

Seminar

Trachoma

David C W Mabe, Anthony W Solomon, Allen Foster

Trachoma is the most common infectious cause of blindness. It is caused by ocular serovars of *Chlamydia trachomatis*. Transmission is favoured in poor communities, where crowding is common and access to water and sanitation inadequate. Repeated reinfection over many years causes dense scarring of the upper eyelid. The resultant inversion of the lashes abrades the eyeball, and the abrasion leads to corneal opacification and visual impairment. The host immune response is probably at least partly the cause of this process. The “SAFE” strategy is used for the control of trachoma: surgery for inverted lashes, antibiotics for active disease, facial cleanliness, and environmental improvement. The demonstration that a single oral dose of the antibiotic azithromycin is as effective as 6 weeks of topical tetracycline was an important advance in trachoma control. By means of the SAFE strategy, WHO and its partners aim to eliminate trachoma as a public-health problem by the year 2020.

Trachoma is an ancient disease, described clearly in the Ebers papyrus of 1500 BC,¹ and well known to the ancient Greeks.² The name comes from the Greek word for rough; a reference to the characteristic appearance of the subtarsal conjunctiva seen when the upper eyelid of an individual with active disease is everted. The disease used to be common in Europe and North America; many of the eye hospitals founded in these regions in the 19th century were established specifically for the treatment of trachoma. The contagious nature of the disease was recognised long before the cause was identified; immigrants to the USA were routinely screened for trachoma on arrival in New York, and sent back to Europe if they had it. Trachoma was a notifiable disease, subject to quarantine, in many European countries. As living standards improved in industrialised countries in the 20th century, trachoma disappeared; the last trachoma isolation hospital in the UK closed in 1947.³ In poor communities in many less developed countries, however, trachoma remains endemic. It ranks in the top three causes of blindness worldwide.⁴

Causative organism

Chlamydial inclusions were first described in conjunctival epithelial cells from patients with trachoma in 1907,⁵ but *C trachomatis* was not isolated in pure culture until 1957.⁶ Koch's postulates were fulfilled soon afterwards, by the inoculation of blind volunteers.⁷

C trachomatis is an obligate intracellular bacterium, one of three chlamydial species that affect human beings. *C psittaci*, a zoonotic pathogen that sporadically infects human beings, and the human pathogen *C pneumoniae* are transmitted by the respiratory route and cause systemic infections. *C trachomatis* is transmitted between human beings by intimate social or sexual contact. Serotypes A, B, Ba, and C cause trachoma, and serotypes D–K cause genital-tract infection. With the exception of the rare lymphogranuloma venereum strains, *C trachomatis* generally remains localised to epithelial surfaces in the eye and genital tract.

The genome of the organism has been sequenced.⁸ Trachoma strains but not genital isolates carry a deletion or frameshift mutation in a variable region encoding genes for tryptophan synthesis.⁹

Chlamydiae cannot replicate outside eukaryotic host cells and have evolved a unique life-cycle in which a metabolically inert, spore-like, infectious elementary body alternates with a metabolically active, intracellular reticulate-body stage (figure 1).¹⁰ *C trachomatis* elementary bodies attach to epithelial cells and are actively taken up into intracellular inclusions. Here elementary bodies differentiate to reticulate bodies, which multiply by binary fission until the inclusion contains several thousand organisms and occupies most of the host-cell cytoplasm. Reticulate bodies then differentiate back into elementary bodies, which are released on lysis of the host cell. This whole process takes 48–72 h in tissue culture.

Natural history and clinical features

Manifestations of ocular disease due to infection with *C trachomatis* depend on the serovar involved and the age of the host. Genital-serovar infection of an infant's eyes during delivery leads to neonatal conjunctivitis (ophthalmia neonatorum), which in most cases is less severe than that due to *Neisseria gonorrhoeae*. Adolescents and adults infected with serovars that normally infect the genital tract can develop a self-limiting follicular conjunctivitis (adult inclusion conjunctivitis).

Trachoma is a chronic keratoconjunctivitis caused by repeated reinfection with the ocular serovars A, B, Ba, and C of *C trachomatis* (panel 1). After an incubation period of 5–10 days, infection with these ocular serovars causes a mild mucopurulent conjunctivitis, which is generally self-limiting and heals without permanent sequelae. Repeated episodes of chlamydial infection (sometimes associated with acute epidemic conjunctivitis due to moraxella or other bacteria) result in signs of chronic inflammation. These are characterised by subepithelial follicles (figure 2) and papillary hypertrophy in the subtarsal conjunctiva, which can be seen after eversion of the upper eyelid. Vascular infiltration of the upper cornea (pannus) is common but rarely progresses to affect vision. Such signs of active disease are seen mainly in young children, but also occur in older children and some adults. Conjunctival follicles at the upper limbal margin of the cornea leave characteristic shallow depressions, known as Herbert's pits, after they resolve.

Search strategy

We did a search of MEDLINE, with no date restriction with the key word “trachoma”, and made use of WHO publications on trachoma and our own personal libraries. We included English language papers.

Lancet 2003; 362: 223–29

Clinical Research Unit, London School of Hygiene and Tropical Medicine, London WC1E 7HT, UK (Prof D C W Mabe FRCP, A W Solomon MB, Prof A Foster FRCOphth)

Correspondence to: Prof David Mabe (e-mail: david.mabe@lshtm.ac.uk)

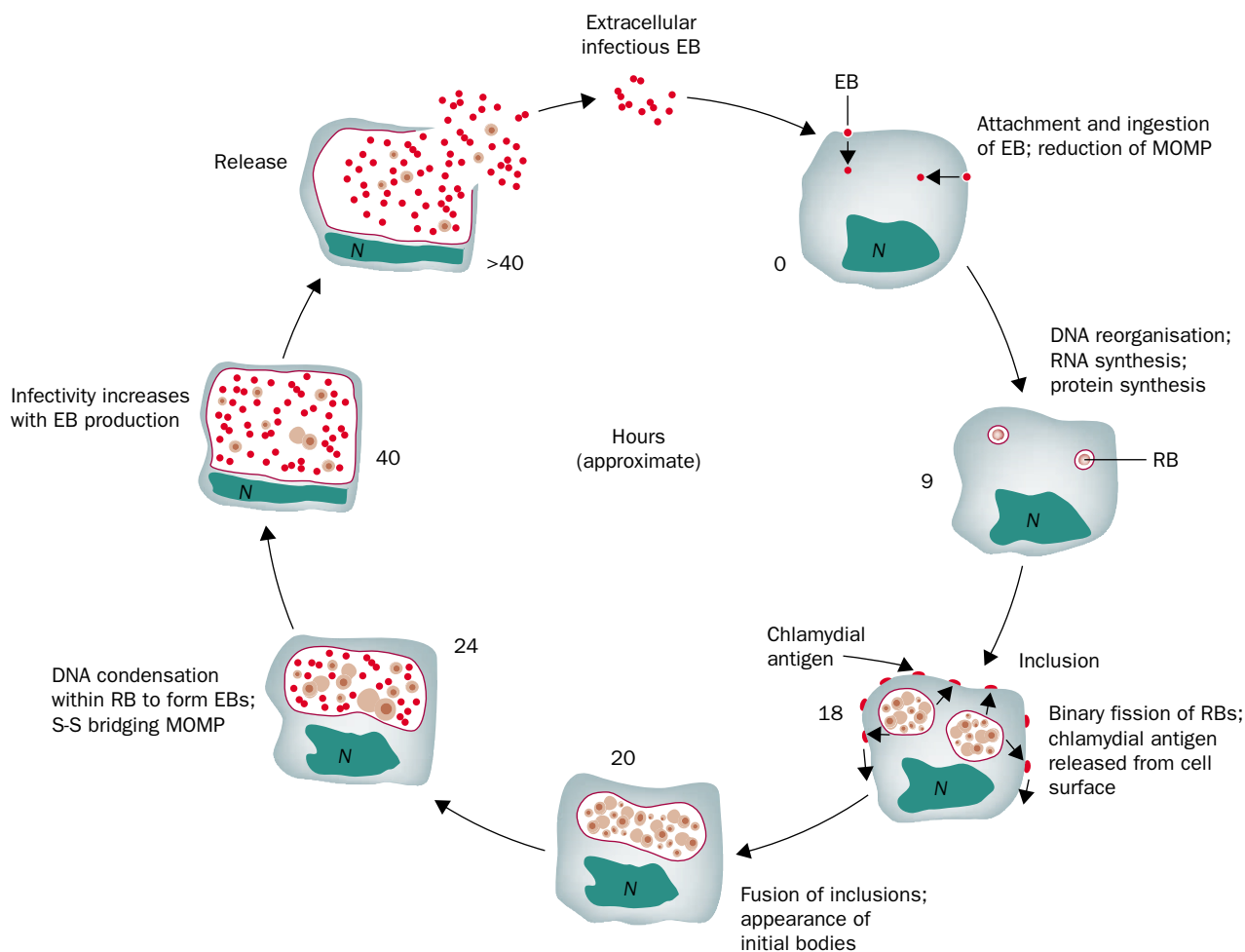


Figure 1: **Life-cycle of *C. trachomatis***

EB=elementary body; MOMP=major outer membrane protein; RB=reticulate body. Adapted from Barron.¹⁰

After years of reinfection, resulting in chronic inflammation, fibrosis leading to scarring appears in the upper sub tarsal conjunctiva (figure 2).¹¹ As the scarring progresses, generally over many years, there is distortion of the lid margin, causing the lashes to turn inwards and rub against the cornea (trichiasis). Constant trauma to the cornea, as well as being painful, leads eventually to corneal opacity and blindness. Although the signs of follicular and inflammatory trachoma and the process of conjunctival scarring are caused by *C. trachomatis*, secondary infection of the traumatised cornea with other bacteria or fungi may also contribute to its opacification.

Pathogenesis

Histopathology

The clinical and pathological hallmark of active trachoma is the conjunctival lymphoid follicle. Follicles contain typical germinal centres consisting predominantly of B lymphocytes, with T lymphocytes (CD8+) in the parafollicular region.¹² Between follicles, the inflammatory infiltrate contains plasma cells, dendritic cells, macrophages, and polymorphonuclear leucocytes in addition to T and B cells.¹³

In individuals with trachomatous conjunctival scarring, there is atrophy of the conjunctival epithelium with loss of goblet cells. Beneath the epithelium, a thick, compact scar replaces the normal loose, vascular stroma. The scar tissue consists mainly of type V collagen, with type IV along the conjunctival basement membrane replacing the looser types (I and III) of collagen that are normally found in the

stroma.¹⁴ A proportion of biopsy samples from scarred individuals show a striking inflammatory infiltrate, in which T lymphocytes (mainly CD4+) outnumber B cells and macrophages.¹⁵

Host immune response

C. trachomatis has evolved various ways to evade the host immune response. First, its intracellular location protects it from attack by antibody and complement. Second, expression of MHC class I molecules at the surface of infected cells is downregulated, reducing the likelihood that the cells will be recognised and killed by class-I-restricted cytotoxic T cells.¹⁶ Last, fusion of the phagosome (containing the ingested organism) with host-cell lysosomes (containing microbicidal substances) is actively prevented.¹⁷

The immune response to *C. trachomatis*, however, has adverse as well as beneficial effects. Whole-cell vaccines investigated in primates and human beings in the 1960s conferred short-lived, serotype-specific protection from ocular challenge. But the trials also showed that on rechallenge, some vaccinated individuals developed more severe disease, which implied that much of the damage associated with ocular chlamydial infection is immunopathological.¹⁸

Studies in trachoma-endemic communities have found that the duration of untreated infection is shorter in older people, which suggests that acquired immunity has a role in the resolution of infection.¹⁹ There is evidence that a cellular immune response to chlamydial antigens of the T-helper (Th) 1 type is important.^{20,21} The Th1 cytokine

Panel 1: Characteristics of the organism and pathogenesis

Known

C trachomatis is an obligate intracellular bacterium.

It has a unique life-cycle involving an infectious, spore-like elementary body and a metabolically active reticulate body.

Serovars A, B, Ba, and C cause endemic trachoma.

Immune mechanisms (probably cell mediated, of the Th1 type) play a part in resolution of infection.

Immune mechanisms contribute to the disease process (inflammation and scarring).

Major outer membrane protein (MOMP) makes up 60% of the elementary-body wall and contains serovar-specific epitopes.

Antibodies to variable, serovar-specific domains of MOMP neutralise *C trachomatis* infection in vitro.

Not known

The pathophysiological pathways that cause inflammation and fibrosis.

The chlamydial antigens that evoke a protective immune response and those that elicit damaging immunopathology.

The significance of the association between serum antibodies to chlamydial hsp60 and scarring trachoma.

Whether the organism exists in a latent form in human beings, and if so, the importance of latent infection in the pathogenesis.

Whether the duration of infection can be shortened or ocular chlamydial infection can be prevented by vaccination without increasing the risk of immunopathological damage.

interferon γ inhibits chlamydial replication in vitro by inducing the degradation of tryptophan, resulting in a state of chlamydial latency, with developmental arrest at the reticulate-body stage.²²

Chlamydial heat-shock protein 60 (hsp60) has been implicated in the pathogenesis of ocular infection in a primate model.²³ Serum antibodies to hsp60 are associated with the presence of conjunctival scarring in human beings.²⁴ Whether the immune response to this protein has a role in the pathogenesis of scarring, or whether serum antibody to hsp60 is merely a marker of persistent infection that itself is more likely to give rise to scarring, is not clear.

In vitro, non-replicating *C trachomatis* treated with interferon gamma continues to produce hsp60.²⁵ Whether a state of true chlamydial latency (ie, the persistence of non-replicating intracellular organisms) occurs in vivo is not known. By use of sensitive DNA-amplification techniques, *C trachomatis* can be detected in the absence of clinical signs of trachoma,^{26,27} but whether this represents latent or inapparent infection, incubating disease, or contamination is not clear.

Vaccine candidates

The major outer membrane protein (MOMP) of *C trachomatis* is an immunodominant antigen, which makes up 60% of the elementary-body cell wall. It contains four variable, surface-exposed regions that confer serotype specificity. Since vaccine-induced immunity is serotype specific, MOMP is a likely candidate for a subunit chlamydial vaccine.¹⁷ Monoclonal antibodies to MOMP neutralise *C trachomatis* infection in vitro, but protection by antibodies against chlamydial infection at mucosal surfaces in the eye and genital tract has not yet been shown.^{28,29}

In a murine model, a MOMP-based DNA vaccine against the mouse pneumonitis strain of *C trachomatis* generated strong cellular immune responses (Th1 type) and reduced the severity of systemic illness.³⁰ However, MOMP-based vaccines have not been shown to protect against ocular *C trachomatis* infection. Possibly the best

we can hope for is a vaccine that will limit the duration of infection and disease, reducing transmission, inflammation, and blinding sequelae, rather than one that will confer total immunity to infection.

Genetic susceptibility

Longitudinal studies in trachoma-endemic communities suggest that some individuals are more likely than others to develop severe inflammatory disease when exposed to *C trachomatis*.³¹ Many of these individuals have persistent

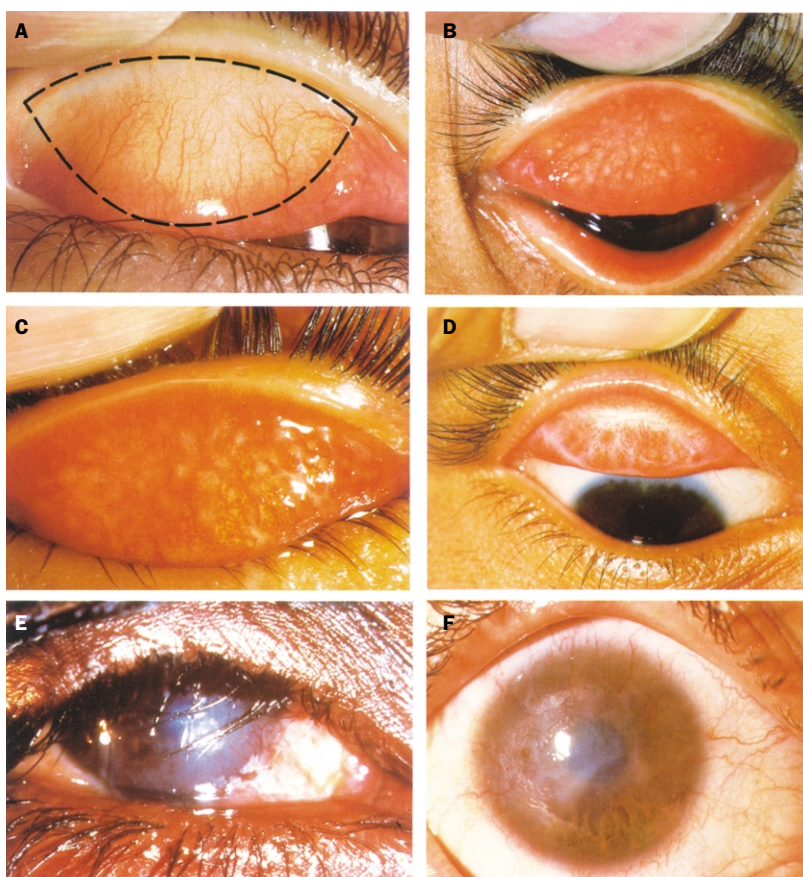


Figure 2: Appearance of trachoma

A: Normal everted upper tarsal conjunctiva; it is pink, smooth, thin, and transparent. Over the whole area of the tarsal conjunctiva, there are normally large deep-lying blood vessels that run vertically. The dotted line shows the area to be examined. B: Trachomatous inflammation-follicular (TF). C: Trachomatous inflammation-follicular and intense (TF + TI). D: Trachomatous scarring (TS). E: Trachomatous trichiasis (TT). F: Corneal opacity (CO). These photographs are reproduced with permission from the WHO Programme for the Prevention of Blindness and Deafness

Panel 2: Simplified grading scheme for assessment of trachoma in communities³⁶

TF—trachomatous inflammation, follicular: the presence of five or more follicles of at least 0.5 mm diameter in the central part of the upper tarsal conjunctiva.

TI—trachomatous inflammation, intense: pronounced inflammatory thickening of the upper tarsal conjunctiva obscuring more than half the normal deep tarsal vessels.

TS—trachomatous conjunctival scarring: the presence of easily visible scars in the tarsal conjunctiva.

TT—trachomatous trichiasis: at least one eyelash rubbing on the eyeball, or evidence of recent removal of in-turned eyelashes.

CO—corneal opacity: easily visible corneal opacity over the pupil, so dense that at least part of the pupil margin is blurred when viewed through the opacity.

infection and persistent clinical signs and are at increased risk of conjunctival scarring.³² Case-control studies in The Gambia have shown associations between trachoma scarring and HLA class II alleles as well as polymorphisms in the promoter region of the gene for tumour necrosis factor α . These findings suggest that genetically determined differences in the immune response to *C trachomatis* influence the natural history of trachoma.^{33,34}

Diagnosis

Examination of an eye for the clinical signs of trachoma involves careful inspection of the lashes and cornea, then eversion of the upper lid and inspection of the upper tarsal conjunctiva. Binocular loupes (magnification $\times 2.5$) and adequate lighting are needed.

A detailed grading scheme published in 1981 by WHO³⁵ is favoured by some researchers, but most surveys and national trachoma programmes now use the WHO simplified grading system.³⁶ This system was designed for assessment of the prevalence and severity of disease in communities and change in prevalence over time; unlike the more detailed system, it was not intended for diagnosis of individual cases. Clinical diagnosis is best made from a history of living in a trachoma-endemic environment, in combination with the full range of clinical signs.

Five grades are included in the simplified system (panel 2). TF is a manifestation of moderately active disease. Small or peripheral follicles do not contribute to a diagnosis of TF, since these may be normal, particularly in children and young adults. TI is a manifestation of severe active disease. Both TF and TI are most prevalent in young children. A frequency of TF greater than 20% or TI greater than 5% in children aged 0–9 years suggests that trachoma is a public-health problem.³⁷ TS is conjunctival scarring due to old disease. A patient with TT is at serious risk of corneal opacity and visual loss. TT is more common in female than male patients,³⁸ and the prevalence increases with age. A helpful approach is to subdivide trichiasis into minor trichiasis (TT), in which lashes do not touch the cornea; and major trichiasis (TT+), in which lashes normally touch the cornea, to help prioritise patients for surgery. Visual acuity should be recorded for patients with TT or CO.

Specificity of clinical signs

Follicles, papillae, conjunctival scarring, and pannus seen alone are not pathognomonic of trachoma. However, if any of these signs are present without another obvious cause in an individual living in a trachoma-endemic community a diagnosis of trachoma can be suspected. Almost all cases of trichiasis of the upper eyelid are due to trachoma. Corneal

opacity can result from various causes and can occur in trachoma-endemic communities even in the absence of trichiasis.

Laboratory diagnosis

Trachoma is, in general, a clinical diagnosis. For research or special survey purposes, various laboratory assays can be used for the diagnosis of ocular *C trachomatis* infection, including examination of stained conjunctival scrapings for intracytoplasmic inclusions, tissue culture, immunofluorescence, ELISA, and nucleic-acid-amplification tests such as PCR.

Tissue culture, although less than 100% sensitive, expensive, and time-consuming, remains an asset for the laboratory diagnosis of chlamydial infection because of its near-perfect specificity.³⁹ It proves that viable organisms are present in the sample (rather than just nucleic acid) and, in specialised laboratories, allows the antimicrobial sensitivities of *C trachomatis* isolates to be elucidated. Although resistance in *C trachomatis* has not yet proven to be a clinical problem, there is potential for it to develop with extensive use of antibiotics. Because annual mass distribution of single-dose azithromycin is now a strategy for trachoma control in some countries, sensitivity testing may be of increasing relevance to policy-makers.

On ocular samples from trachoma-endemic populations, nucleic-acid-amplification tests return a higher proportion of positive results than other assays.^{26,40} They are therefore considered to be more sensitive than other tests. Four nucleic-acid-amplification tests are commercially available for the diagnosis of *C trachomatis* infection: Amplicor (Roche), which uses PCR; LCx (Abbott), which uses the ligase chain reaction; AMP-CT (Gen-Probe), which uses transcription-mediated amplification; and ProbeTec (Becton Dickinson), which uses a strand-displacement assay. All were developed primarily for the diagnosis of urogenital chlamydial infections and have therefore been most extensively evaluated for that application. Only Amplicor⁴¹ and LCx^{27,42–44} have been used for the diagnosis of ocular chlamydial infection in studies published to date. However, because all four commercial tests have comparable performance characteristics for urogenital samples, the decision as to which might be most appropriate in a particular setting can probably be made on the basis of cost, availability, and familiarity.⁴⁵

The positive predictive value of clinical diagnosis of trachoma falls with decreasing prevalence. Baral and colleagues postulated that, in individuals who have previously had active trachoma, stimuli other than chlamydial infection may reactivate the follicular response.⁴³ As a result, microbiological diagnosis will have a role in surveillance and certifying cessation of transmission.

Relation between infection and disease

Even with the most sensitive and specific tests available, the correlation between clinical signs of the WHO grading system and laboratory positivity is less than perfect. This lack of congruity is partly a function of the arbitrary nature of the simplified grading scheme, which labels five follicles “disease” but four follicles “normal”, and designates papillary conjunctivitis in which more than half the deep tarsal vessels are obscured TI, though the stimulus for inflammation may be micro-organisms other than *C trachomatis*. Some of the discrepancy between examination findings and swab results probably also reflects the natural history of ocular *C trachomatis* infection. The development and resolution of signs may lag behind the start and finish of the period of laboratory positivity. In other words, active disease becomes clinically apparent

Panel 3: SAFE strategy**Known**

Trichiasis in a proportion of patients leads, over years, to corneal opacity and blindness.
 Tarsal rotation is a successful procedure to treat trichiasis in trachoma control programmes.
 Communities with a high frequency of TF and TI in young children generally have a high frequency of TT and CO in the adult population.
 Children younger than 5 years are the main reservoir for chlamydial infection and transmission.
 Single-dose oral azithromycin is at least as effective as 6 weeks of tetracycline ointment in active trachoma (TF/TI).
 Oral azithromycin has negligible side-effects, and compliance is better than with tetracycline eye ointment.
 Dirty faces are associated with trachoma; health education can lead to clean faces in children.
 Preliminary studies suggest that the provision of latrines reduces the number of *Musca sorbens* flies and lowers the prevalence of active trachoma.

Not known

Whether epilation is a sufficient treatment for one to three lateral eyelashes with no corneal damage.
 Which individuals should be given azithromycin.
 How often azithromycin should be given in different settings.
 How to make clean faces in infants a "norm" for a society.
 How to reduce numbers of eye-seeking flies in an affordable, sustainable, and locally acceptable way.

some weeks after infection, and a similar period can elapse between clearance of organisms and the disappearance of clinical disease.²⁶ Sample contamination, and (the postulated) persistent latent infection with *C trachomatis*⁴⁶ are also possible explanations.

Epidemiology

Trachoma is endemic in 48 countries including large areas of the Middle East and Africa, with focal areas of disease in south and central Asia, Latin America, and Australasia. Current estimates are that active trachoma affects some 150 million people worldwide, more than 10 million have trichiasis, and about 6 million people are blind from corneal scarring.⁴ Active disease is most commonly seen in children, and the complications leading to visual loss and blindness in adults, with several times excess risk for women.^{38,47}

Trachoma is a focal disease affecting certain communities and within these communities some households. Many studies have identified various risk factors associated with trachoma. Some factors appear to be locally specific, and others are obvious markers of poverty. The characteristics of households affected by trachoma are that they have young children and poor living conditions, specifically inadequate access to water and sanitation.

Infection can be transmitted from eye to eye by fingers, shared cloths or towels, by coughing or sneezing (since *C trachomatis* can be found in the nasopharynx⁴⁸ and external nasal exudate⁴⁹ of children with trachoma), or by eye-seeking flies. The relative importance of these routes of transmission is not clear, and probably varies from one endemic community to another.

Management

Activities to control trachoma are interventions undertaken with the community, rather than treatment for individuals in medical facilities. The aim of trachoma control can be to prevent visual loss and blindness; decrease the level of infection so that trachoma is no longer a public-health problem; or eliminate trachoma from a population. The

strategy recommended by WHO⁵⁰ is known by the acronym SAFE: S for surgery for trichiasis/entropion (TT); A for antibiotics for active disease (TF/TI); F for facial cleanliness through personal hygiene; and E for environment improvement with education and improved local economy.

Once endemic trachoma has been identified in a community, the first priority is to lower the immediate risk of further visual loss in individuals with potentially blinding trichiasis. The second step is to reduce the severity of active disease (inflammation) and suppress transmission of ocular *C trachomatis* through antibiotic treatment. Action can then be taken to remove the risk factors that encourage transmission of infection. SAFE therefore describes a comprehensive plan of interventions, implemented in a community, to treat the different stages of trachoma and address the risk factors predisposing to disease transmission (panel 3).

Surgery for trichiasis

Many different procedures have been described to correct trichiasis and entropion. Reacher and colleagues undertook a review of the various methods and carried out two randomised surgical trials.^{51,52} Division of the upper-eyelid tarsal plate with external rotation of the distal margin by use of three or four sutures (tarsal rotation) gave the best results, with at least 70% success at 6–24 months after surgery. Some programmes have advocated repeated epilation for patients who have only a few in-turned eyelashes and no evidence of damage to the cornea.

Studies in Africa suggest that if patients with trichiasis are identified in a community and asked to attend a nearby health facility for surgery, fewer than one in three attend.^{53–55} Bowman and co-workers showed that surgery offered in the village at no cost had a better acceptance rate.⁵⁶ An eye nurse working in Tanzania did tarsal rotation in the community and reported 80% success at 2 years, and more than 95% success if successful outcomes included one or two lateral in-turned eyelashes not touching the cornea.⁵⁷

In summary, the surgery component involves identification of individuals with trichiasis and offering them a tarsal rotation procedure, within the community, by a well-trained eye nurse or assistant, at little or no cost to the patient.

Antibiotics

The recommended treatment for active trachoma is topical tetracycline, twice daily for 6 weeks.³⁵ Tetracycline ointment is irritating and difficult to use, particularly in infants, so compliance is poor. Three randomised controlled trials^{58–60} have established that one 20 mg/kg dose of azithromycin is at least as effective as supervised application of tetracycline ointment. When tubes of ointment are simply given to patients and parents for use at home, single-dose azithromycin is more effective, particularly for individuals with intense inflammation (TI).⁶¹ Azithromycin has the added benefit of treating extraocular reservoirs of chlamydial infection, and although there must be caution to avoid emergence of resistance in chlamydia and other bacteria,^{62–64} current evidence supports the use of azithromycin. Pfizer, through the International Trachoma Initiative, have generously donated azithromycin for use in SAFE programmes in ten countries. Where azithromycin is not yet available or affordable, tetracycline ointment remains an alternative treatment.

Who should receive treatment? Suggested strategies include: all children;⁴² all inhabitants of any household which has an individual with TF or TI;⁶⁵ and all inhabitants of a village with endemic trachoma.²⁷ If antibiotics are given

only to individuals with clinical evidence of TF or TI and their families, reinfection is likely to occur more rapidly. However, this may be an appropriate strategy for a community with a low frequency of active disease. Mass treatment requires more antibiotic, but may be a more effective⁴² and cost-effective⁶⁶ approach for communities with moderate or high frequency of active disease.

Recent studies have shown that children younger than 5 years of age have the highest ocular chlamydial loads, and even those younger than 1 year old constitute a significant reservoir of infection.⁴¹ Some trachoma-control programmes using azithromycin currently do not offer the drug to infants younger than 1 year old. If transmission of *C trachomatis* is to be stopped or significantly reduced, the age-groups shedding most organism must be adequately treated with antibiotic.

How often should antibiotic distribution be done? Initial models for determining treatment frequency⁶⁷ are yet to be validated. Currently, annual treatment is recommended, but treatment should probably be given more often in populations with high rates of trachoma transmission and perhaps less often in populations where trachoma is on the wane.

Thus, azithromycin is an important new tool for the control of active disease and reduction in disease transmission. Optimum use of the antibiotic needs to be defined for communities with high, moderate, and low endemicities.

Facial cleanliness

Anecdotal reports have suggested that face washing protects against trachoma, and observational studies have shown that unclean faces are associated with TF and TI.^{68,69} There has been one well-conducted community intervention trial comparing (in a high-frequency area) antibiotic treatment alone versus antibiotic treatment combined with an intensive health education programme about facial cleanliness.⁷⁰ Antibiotics lowered the frequency of TF and TI in all communities, but active disease was returning towards pretreatment levels by 12 months. The health education programme prolonged the reduction in the prevalence of severe trachoma (TI): this difference between intervention and control groups was significant. Although no significant effect on the prevalence of TF at 1 year could be attributed to health education in this study, the education programme significantly increased the proportion of sustained clean faces in children, and clean faces were protective against TF and TI.⁷⁰

Environmental improvement

This component is the least well defined, but probably the most important element of the SAFE strategy. Trachoma disappeared from Europe and North America as a result of improved living conditions, not as a result of antibiotics or surgical treatment. Since socioeconomic improvement may be slow in many communities where trachoma remains endemic, specific interventions have been recommended to reduce the risk of transmission of ocular *C trachomatis* infection. None of these has been proven to be effective through randomised controlled trials. They include environment improvement through, for example, increasing access to water, use of latrines and other fly control interventions, and moving animals (eg, cows) away from the household environment; education, both general and specific for trachoma; and improved local economy leading to better living conditions.

Emerson and colleagues found that insecticide spraying or provision of latrines could produce a reduction in flies (specifically the eye-seeking *Musca sorbens*), which in turn

produces a reduction in active trachoma and in diarrhoeal disease.⁷¹ These important initial studies need to be expanded to find out whether fly control can be made affordable, sustainable, and acceptable to the community.

Effective control of trachoma requires prolonged effort and is best integrated with local health systems and other development sectors. Perhaps most importantly, though, affected communities must be included during planning, to ensure that they develop a sense of ownership of the SAFE strategy. The full and active involvement of all stakeholders will be required to achieve the WHO-supported goal of the global elimination of trachoma as a public-health problem by the year 2020.⁷²

Conflict of interest statement

We have received research grants from the International Trachoma Initiative, a non-profit organisation supported by Pfizer, the manufacturers of azithromycin.

Acknowledgments

We thank the International Trachoma Initiative, the Wellcome Trust, and the Medical Research Council for supporting our research on trachoma. Agencies funding our research were not involved in preparation of this seminar or in the decision to submit it for publication.

References

- Bryan CP. The papyrus Ebers: translated from the German version. London: Bles, 1930.
- Duke-Elder WS. Textbook of ophthalmology. London: Henry Kimpton, 1937.
- Jones BR. The prevention of blindness from trachoma. *Trans Ophthalmol Soc UK* 1975; **95**: 16–33.
- Thylefors B, Negrel AD, Pararajasegaram R, Dadzie KY. Global data on blindness. *Bull World Health Organ* 1995; **73**: 115–21.
- Halberstaedter L, von Prowazek S. Uber Zelleinschlusse parasitaerer Natur beim Trachom. *Arb Gesundhamt Berlin* 1907; **26**: 44–47.
- Tang FF, Chang HL, Huang YT, Wang KC. Studies on the etiology of trachoma with special reference to isolation of the virus in chick embryo. *Chin Med J* 1957; **75**: 429–47.
- Collier LH, Duke-Elder S, Jones BR. Experimental trachoma produced by cultured virus. *Br J Ophthalmol* 1958; **42**: 705–20.
- Stephens RS, Kalman S, Lammel C, et al. Genome sequence of an obligate intracellular pathogen of humans: Chlamydia trachomatis. *Science* 1998; **282**: 754–59.
- Fehlner-Gardiner C, Roshick C, Carlson JH, et al. Molecular basis defining human *Chlamydia trachomatis* tissue tropism: a possible role for tryptophan synthase. *J Biol Chem* 2002; **277**: 26893–903.
- Barron AL. Microbiology of chlamydia. Boca Raton: CRC Press, 1988.
- Grayston JT, Wang SP, Yeh LJ, Kuo CC. Importance of reinfection in the pathogenesis of trachoma. *Rev Infect Dis* 1985; **7**: 717–25.
- Whittum-Hudson JA, Taylor HR, Farazdaghi M, Prendergast RA. Immunohistochemical study of the local inflammatory response to chlamydial ocular infection. *Invest Ophthalmol Vis Sci* 1986; **27**: 64–69.
- el-Asrar AM, Van den Oord JJ, Geboes K, Missotten L, Emarah MH, Desmet V. Immunopathology of trachomatous conjunctivitis. *Br J Ophthalmol* 1989; **73**: 276–82.
- Abu el-Asrar AM, Geboes K, al-Kharashi SA, Tabbara KF, Missotten L. Collagen content and types in trachomatous conjunctivitis. *Eye* 1998; **12**: 735–39.
- Reacher MH, Pe'er J, Rapoza PA, Whittum-Hudson JA, Taylor HR. T cells and trachoma: their role in cicatricial disease. *Ophthalmology* 1991; **98**: 334–41.
- Zhong G, Liu L, Fan T, Fan P, Ji H. Degradation of transcription factor RFX5 during the inhibition of both constitutive and interferon gamma-inducible major histocompatibility complex class I expression in chlamydia-infected cells. *J Exp Med* 2000; **191**: 1525–34.
- Brunham RC. Human immunity to Chlamydiae. In: Stephens RS, ed. Chlamydia. Washington DC: American Society for Microbiology, 1999: 211–38.
- Wang SP, Grayston JT, Alexander ER. Trachoma vaccine studies in monkeys. *Am J Ophthalmol* 1967; **63** (suppl): 1615–30.
- Bailey R, Duong T, Carpenter R, Whittle H, Mabey D. The duration of human ocular *Chlamydia trachomatis* infection is age dependent. *Epidemiol Infect* 1999; **123**: 479–86.
- Bailey RL, Holland MJ, Whittle HC, Mabey DC. Subjects recovering from human ocular chlamydial infection have enhanced lymphoproliferative responses to chlamydial antigens compared with those of persistently diseased controls. *Infect Immun* 1995; **63**: 389–92.
- Holland MJ, Bailey RL, Hayes LJ, Whittle HC, Mabey DC.

- Conjunctival scarring in trachoma is associated with depressed cell-mediated immune responses to chlamydial antigens. *J Infect Dis* 1993; **168**: 1528–31.
- 22 Beatty WL, Belanger TA, Desai AA, Morrison RP, Byrne GI. Tryptophan depletion as a mechanism of gamma interferon-mediated chlamydial persistence. *Infect Immun* 1994; **62**: 3705–11.
- 23 Morrison RP, Lyng K, Caldwell HD. Chlamydial disease pathogenesis: ocular hypersensitivity elicited by a genus-specific 57-kD protein. *J Exp Med* 1989; **169**: 663–75.
- 24 Peeling RW, Bailey RL, Conway DJ, et al. Antibody response to the 60-kDa chlamydial heat-shock protein is associated with scarring trachoma. *J Infect Dis* 1998; **177**: 256–59.
- 25 Beatty WL, Morrison RP, Byrne GI. Persistent chlamydiae: from cell culture to a paradigm for chlamydial pathogenesis. *Microbiol Rev* 1994; **58**: 686–99.
- 26 Bailey RL, Hampton TJ, Hayes LJ, Ward ME, Whittle HC, Mabey DC. Polymerase chain reaction for the detection of ocular chlamydial infection in trachoma-endemic communities. *J Infect Dis* 1994; **170**: 709–12.
- 27 Schachter J, West SK, Mabey D, et al. Azithromycin in control of trachoma. *Lancet* 1999; **354**: 630–35.
- 28 Peeling R, Maclean IW, Brunham RC. In vitro neutralization of *Chlamydia trachomatis* with monoclonal antibody to an epitope on the major outer membrane protein. *Infect Immun* 1984; **46**: 484–88.
- 29 Bailey RL, Kajaf M, Whittle HC, Ward ME, Mabey DC. The influence of local antichlamydial antibody on the acquisition and persistence of human ocular chlamydial infection: IgG antibodies are not protective. *Epidemiol Infect* 1993; **111**: 315–24.
- 30 Zhang D, Yang X, Berry J, Shen C, McClarty G, Brunham RC. DNA vaccination with the major outer-membrane protein gene induces acquired immunity to *Chlamydia trachomatis* (mouse pneumonitis) infection. *J Infect Dis* 1997; **176**: 1035–40.
- 31 Mabey DC, Bailey RL, Ward ME, Whittle HC. A longitudinal study of trachoma in a Gambian village: implications concerning the pathogenesis of chlamydial infection. *Epidemiol Infect* 1992; **108**: 343–51.
- 32 Bobo LD, Novak N, Munoz B, Hsieh YH, Quinn TC, West S. Severe disease in children with trachoma is associated with persistent *Chlamydia trachomatis* infection. *J Infect Dis* 1997; **176**: 1524–30.
- 33 Conway DJ, Holland MJ, Bailey RL, et al. Scarring trachoma is associated with polymorphism in the tumor necrosis factor alpha (TNF-alpha) gene promoter and with elevated TNF-alpha levels in tear fluid. *Infect Immun* 1997; **65**: 1003–06.
- 34 Conway DJ, Holland MJ, Campbell AE, et al. HLA class I and II polymorphisms and trachomatous scarring in a *Chlamydia trachomatis*-endemic population. *J Infect Dis* 1996; **174**: 643–46.
- 35 Dawson CR, Jones BR, Tarizzo ML. Guide to trachoma control in programmes for the prevention of blindness. Geneva: World Health Organization, 1981.
- 36 Thylefors B, Dawson CR, Jones BR, West SK, Taylor HR. A simple system for the assessment of trachoma and its complications. *Bull World Health Organ* 1987; **65**: 477–83.
- 37 WHO. Primary health care level management of trachoma (WHO/PBL/93.33). Geneva: World Health Organization, 1993.
- 38 Treharne JD. The community epidemiology of trachoma. *Rev Infect Dis* 1985; **7**: 760–64.
- 39 Ward ME. Classic diagnostic methods: cell culture. Text at: http://www.chlamydiae.com/restricted/docs/labtests/diag_cellcult.htm (accessed Jan 10, 2002).
- 40 Bobo L, Munoz B, Viscidi R, Quinn T, Mkocho H, West S. Diagnosis of *Chlamydia trachomatis* eye infection in Tanzania by polymerase chain reaction/enzyme immunoassay. *Lancet* 1991; **338**: 847–50.
- 41 Mabey D, Holland M, Solomon A, et al. The epidemiology of ocular *Chlamydia trachomatis* infection in a trachoma endemic community determined by quantitative PCR. In: Schachter J, Christiansen G, Clarke IN, et al, eds. Chlamydial infections: Proceedings of the tenth international symposium on human chlamydial infections. Antalya, Turkey, 2002.
- 42 Holm SO, Jha HC, Bhatta RC, et al. Comparison of two azithromycin distribution strategies for controlling trachoma in Nepal. *Bull World Health Organ* 2001; **79**: 194–200.
- 43 Baral K, Osaki S, Shrestha B, et al. Reliability of clinical diagnosis in identifying infectious trachoma in a low-prevalence area of Nepal. *Bull World Health Organ* 1999; **77**: 461–66.
- 44 Dawson C, Munoz B, Shama A, et al. Antibiotic treatment of trachoma in the Egyptian arm of the ACT trial: laboratory testing and clinical examinations. In: Schachter J, Christiansen G, Clarke IN, et al, eds. Chlamydial infections: Proceedings of the tenth international symposium on human chlamydial infections. Antalya, Turkey, 2002.
- 45 Schachter J, Moncada J. Nucleic acid amplification tests to diagnose *Chlamydia trachomatis* genital infection: the glass is more than half full. In: Schachter J, Christiansen G, Clarke IN, et al, eds. Chlamydial infections: Proceedings of the tenth international symposium on human chlamydial infections. Antalya, Turkey, 2002.
- 46 Ward M, Bailey R, Lesley A, Kajaf M, Robertson J, Mabey D. Persisting inapparent chlamydial infection in a trachoma endemic community in The Gambia. *Scand J Infect Dis Suppl* 1990; **69**: 137–48.
- 47 Faal H, Minassian D, Sowa S, Foster A. National survey of blindness and low vision in The Gambia: results. *Br J Ophthalmol* 1989; **73**: 82–87.
- 48 Malaty R, Zaki S, Said ME, Vastine DW, Dawson DW, Schachter J. Extraocular infections in children in areas with endemic trachoma. *J Infect Dis* 1981; **143**: 853.
- 49 Solomon A, Mabey D, Holland M, et al. Quantification of nasal *Chlamydia trachomatis* infection in a trachoma endemic area of Tanzania. In: Schachter J, Christiansen G, Clarke IN, et al, eds. Chlamydial infections: Proceedings of the tenth international symposium on human chlamydial infections. Antalya, Turkey, 2002.
- 50 WHO. Global elimination of blinding trachoma. Geneva, World Health Organization 51st World Health Assembly, Resolution 51.11, 1998. Text at <http://who.int/pbd/trachoma/wha51-e.htm> (accessed June 13, 2002).
- 51 Reacher MH, Munoz B, Alghassany A, Daar AS, Elbualy M, Taylor HR. A controlled trial of surgery for trachomatous trichiasis of the upper lid. *Arch Ophthalmol* 1992; **110**: 667–74.
- 52 Reacher MH, Huber MJ, Canagaratnam R, Alghassany A. A trial of surgery for trichiasis of the upper lid from trachoma. *Br J Ophthalmol* 1990; **74**: 109–13.
- 53 Oliva MS, Munoz B, Lynch M, Mkocho H, West SK. Evaluation of barriers to surgical compliance in the treatment of trichiasis. *Int Ophthalmol* 1997; **21**: 235–41.
- 54 West S, Lynch M, Munoz B, Katala S, Tobin S, Mmbaga BB. Predicting surgical compliance in a cohort of women with trichiasis. *Int Ophthalmol* 1994; **18**: 105–09.
- 55 Courtright P. Acceptance of surgery for trichiasis among rural Malawian women. *East Afr Med J* 1994; **71**: 803–04.
- 56 Bowman RJ, Soma OS, Alexander N, et al. Should trichiasis surgery be offered in the village? A community randomised trial of village vs. health centre-based surgery. *Trop Med Int Health* 2000; **5**: 528–33.
- 57 Bog H, Yorston D, Foster A. Results of community-based eyelid surgery for trichiasis due to trachoma. *Br J Ophthalmol* 1993; **77**: 81–83.
- 58 Dawson CR, Schachter J, Sallam S, Sheta A, Rubinstein RA, Washon H. A comparison of oral azithromycin with topical oxytetracycline/polymyxin for the treatment of trachoma in children. *Clin Infect Dis* 1997; **24**: 363–68.
- 59 Tabbara KF, Abu-el-Asrar A, al-Omar O, Choudhury AH, al-Faisal Z. Single-dose azithromycin in the treatment of trachoma: a randomized, controlled study. *Ophthalmology* 1996; **103**: 842–46.
- 60 Bailey RL, Arullendran P, Whittle HC, Mabey DC. Randomised controlled trial of single-dose azithromycin in treatment of trachoma. *Lancet* 1993; **342**: 453–56.
- 61 Bowman RJ, Sillah A, Van Dehn C, et al. Operational comparison of single-dose azithromycin and topical tetracycline for trachoma. *Invest Ophthalmol Vis Sci* 2000; **41**: 4074–79.
- 62 Chern KC, Shrestha SK, Cevallos V, et al. Alterations in the conjunctival bacterial flora following a single dose of azithromycin in a trachoma endemic area. *Br J Ophthalmol* 1999; **83**: 1332–35.
- 63 Leach AJ, Shelby-James TM, Mayo M, et al. A prospective study of the impact of community-based azithromycin treatment of trachoma on carriage and resistance of *Streptococcus pneumoniae*. *Clin Infect Dis* 1997; **24**: 356–62.
- 64 Somani J, Bhullar VB, Workowski KA, Farshy CE, Black CM. Multiple drug-resistant *Chlamydia trachomatis* associated with clinical treatment failure. *J Infect Dis* 2000; **181**: 1421–27.
- 65 Solomon AW, Akudibillah J, Abugri P, et al. Pilot study of the use of community volunteers to distribute azithromycin for trachoma control in Ghana. *Bull World Health Organ* 2001; **79**: 8–14.
- 66 Frick KD, Lietman TM, Holm SO, Jha HC, Chaudhary JS, Bhatta RC. Cost-effectiveness of trachoma control measures: comparing targeted household treatment and mass treatment of children. *Bull World Health Organ* 2001; **79**: 201–07.
- 67 Lietman T, Porco T, Dawson C, Blower S. Global elimination of trachoma: how frequently should we administer mass chemotherapy? *Nat Med* 1999; **5**: 572–76.
- 68 West SK, Congdon N, Katala S, Mele L. Facial cleanliness and risk of trachoma in families. *Arch Ophthalmol* 1991; **109**: 855–57.
- 69 Taylor HR, West SK, Mmbaga BB, et al. Hygiene factors and increased risk of trachoma in central Tanzania. *Arch Ophthalmol* 1989; **107**: 1821–25.
- 70 West S, Munoz B, Lynch M, et al. Impact of face-washing on trachoma in Kongwa, Tanzania. *Lancet* 1995; **345**: 155–58.
- 71 Emerson PM, Lindsay SW, Walraven GE, et al. Effect of fly control on trachoma and diarrhoea. *Lancet* 1999; **353**: 1401–03.
- 72 WHO. Planning for the global elimination of trachoma (GET): report of a WHO consultation (WHO/PBL/97.60). Geneva: World Health Organization, 1997.