

Case I

History I

- 70-year old qatari male, December 2007
 - 2 months history of thrombocytopenia, associated with back pain and difficulties in walking

Investigated in Qatar 11/2007:

- Blood film showed a leukoerythroblastic anaemia with 4% blasts and pancytopenia
- Bone marrow aspirate and trephine showed marked fibrosis, infiltration with abnormal cells noted

History II

- CT of chest, abdomen and pelvis:
Pulmonary emphysema and bilateral adrenal masses
- Bone scan:
focal uptake in ribs and femora
- Adrenal biopsy: showed possible carcinoma
- Unable to make further diagnosis in Qatar
- Rapid deterioration of the patient

Examination I

- Transfer to London on the 30/11/2007 for further investigation and diagnosis:
 - On arrival:
 - Bedbound, in pain
 - Pale, jaundiced
 - Apyrexial
 - Multiple subcutaneous hard nodules across the anterior chest wall
 - Abdominal examination reveals enlarged liver
 - Neurological examination shows a 4/5 weakness of the R hip flexors only

Investigation I

- FBC & Flowcytometry
- Blood film
- Bone marrow aspirate & trephine
(H&E, DE, SBB, and Immunohistochemistry)
- Skin biopsy
(H&E and Immunohistochemistry)
- What is the likely diagnosis?

Full Blood Count

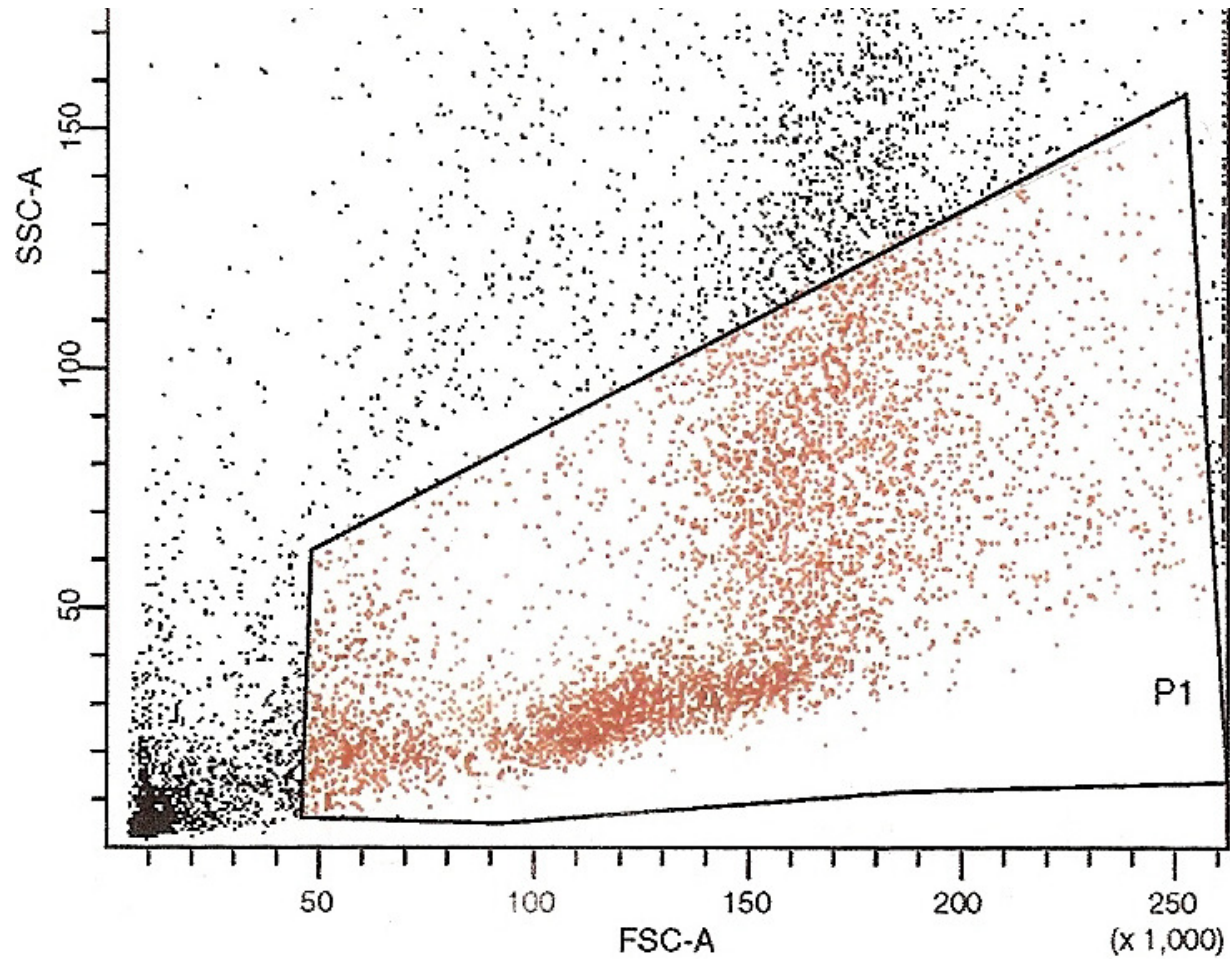
Date of Birth: 01/01/1936	
Sex: M	
Laboratory Number: 07H294852	Specimen Received: 07/12/07 at 12:21
Ref. Lab. Details:	

Test Name	Results		Units	Reference Range
FULL BLOOD COUNT				
Hb	9.4	L	g/dL	11.5-17.0
WBC	11.06	H	10 ⁹ /L	3.5-11
Platelets	27	L	10 ⁹ /L	140-400
RBC	3.62	L	10 ¹² /L	3.9-5.6
HCT	0.299	L	L/L	0.35-0.47
MCV	82.5		fL	80-98
MCH	26.1	L	pg	27-33
MCHC	31.6		g/dL	31-37
Neutrophils	4.87		10 ⁹ /L	1.7-8.0
Lymphocytes	4.20	H	10 ⁹ /L	1.0-3.5
Monocytes	0.00	L	10 ⁹ /L	0.1-1.0
Eosinophils	0.00		10 ⁹ /L	0.0-0.46
Basophils	0.00		10 ⁹ /L	0.00-0.20
Blast cells	0.44		10 ⁹ /L	
Promyelocytes	1.11		10 ⁹ /L	
Myelocytes	0.00		10 ⁹ /L	
Metamyelocytes	0.44		10 ⁹ /L	
Nucleated RBC	28			

Film Report

Manual differential reported. Anisocytosis
Dimorphic population, Polychromasia +++,
Thrombocytopenia confirmed on film.

Scattergram I



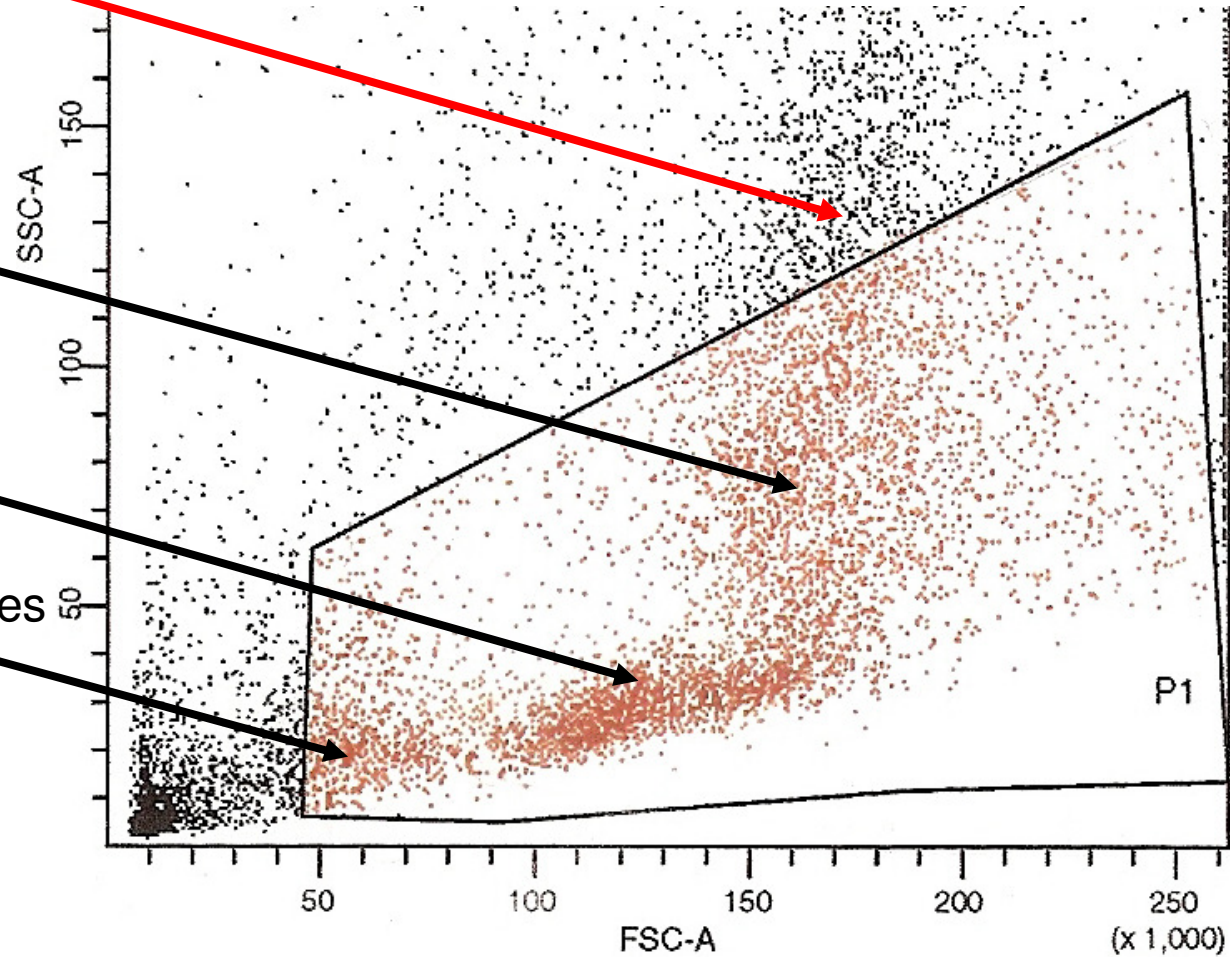
Scattergram I

Neutrophils

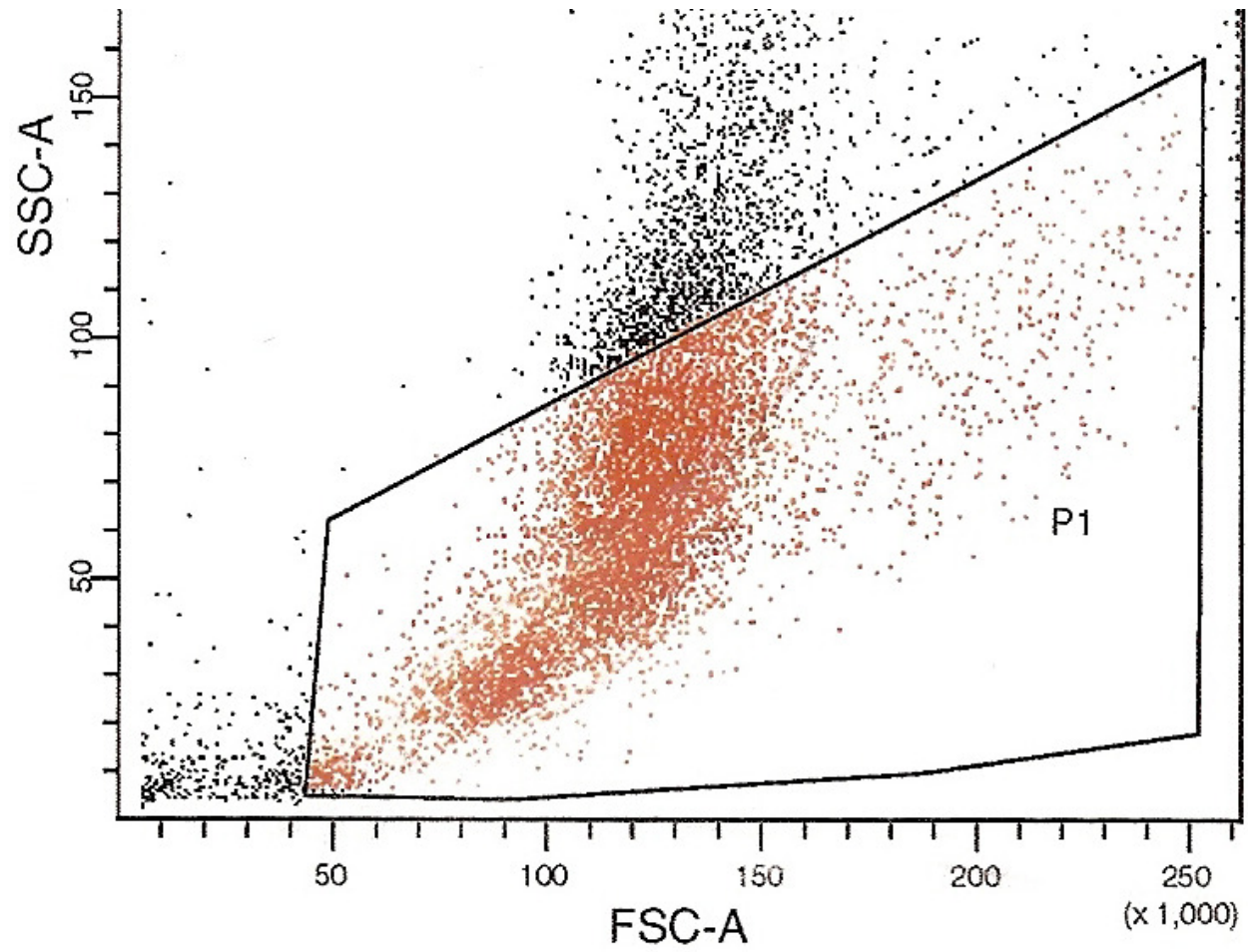
Myelocytes

Blasts

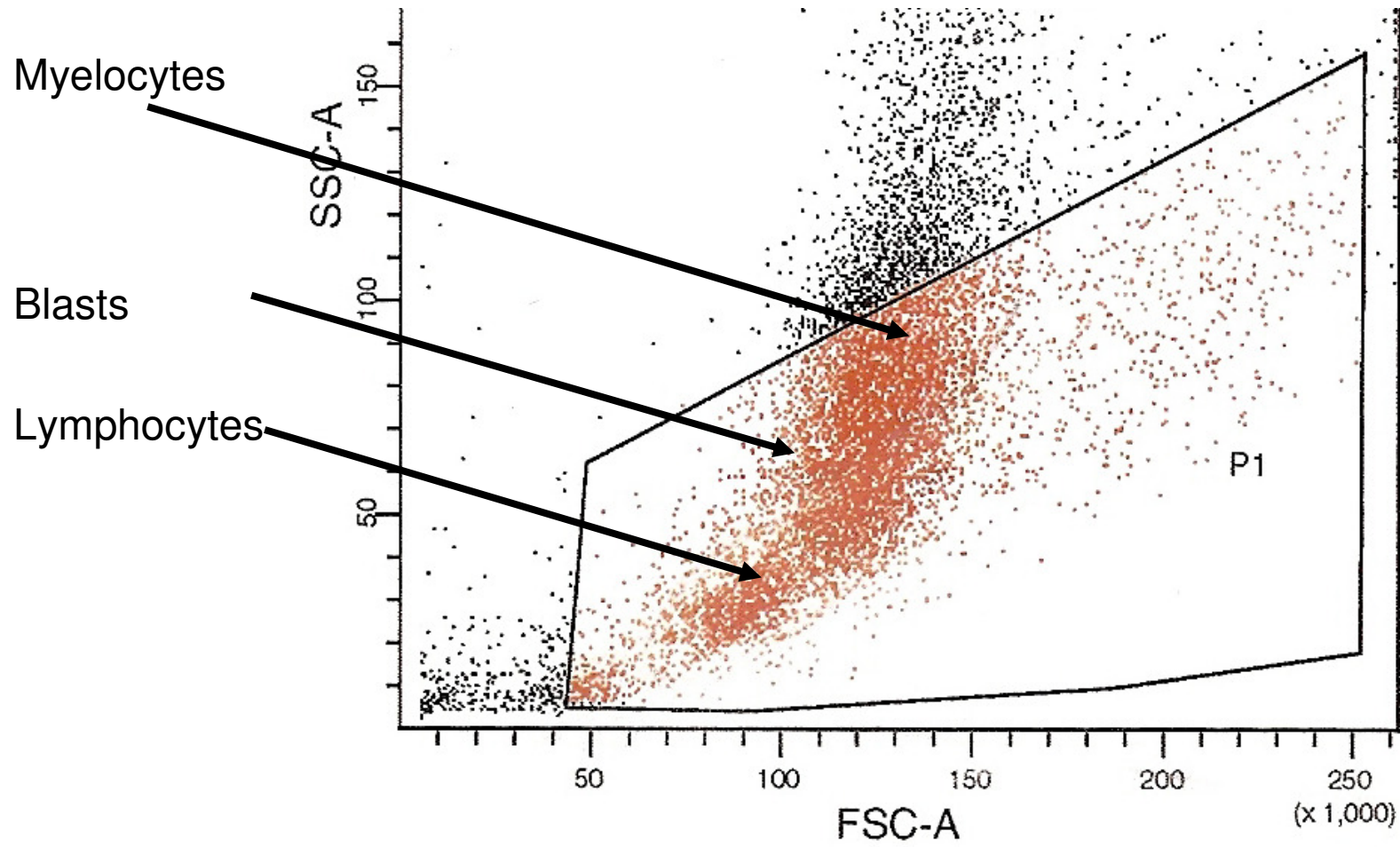
Lymphocytes



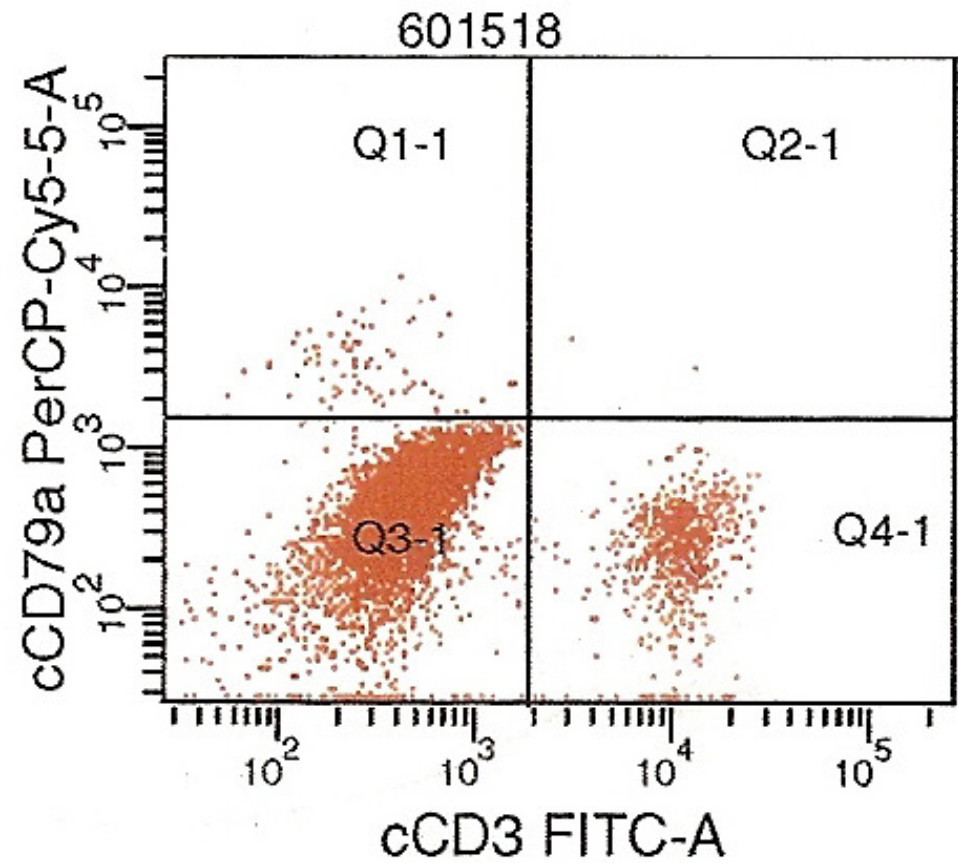
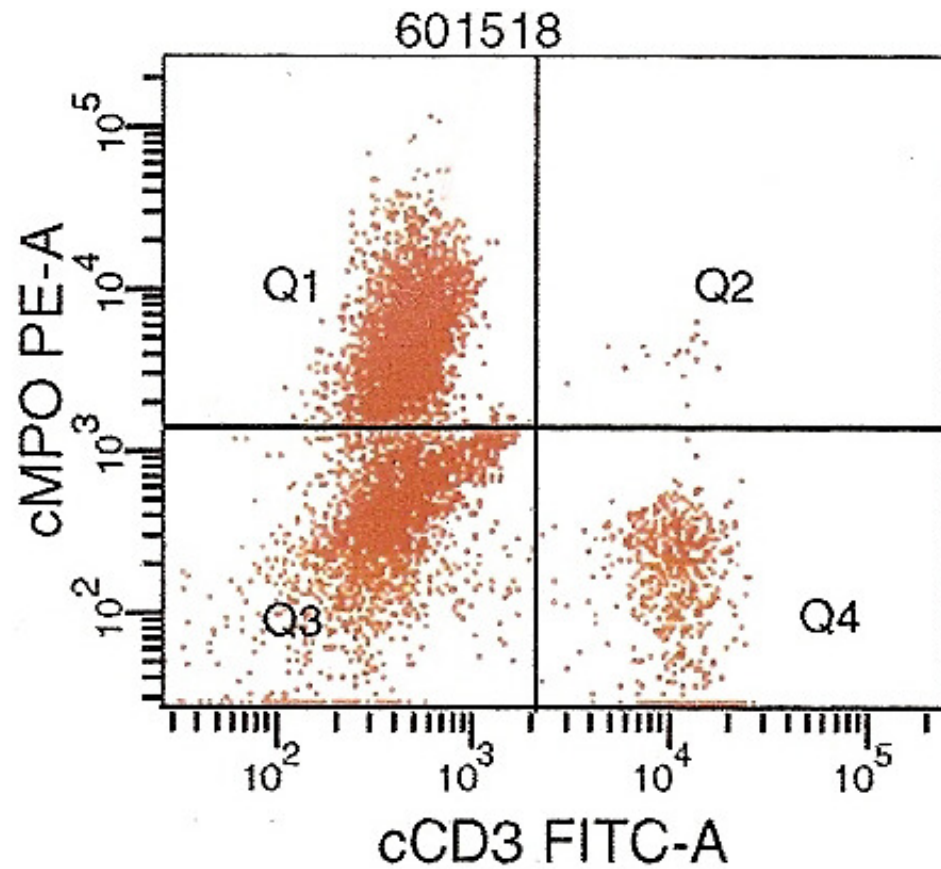
Scattergram II



Scattergram II

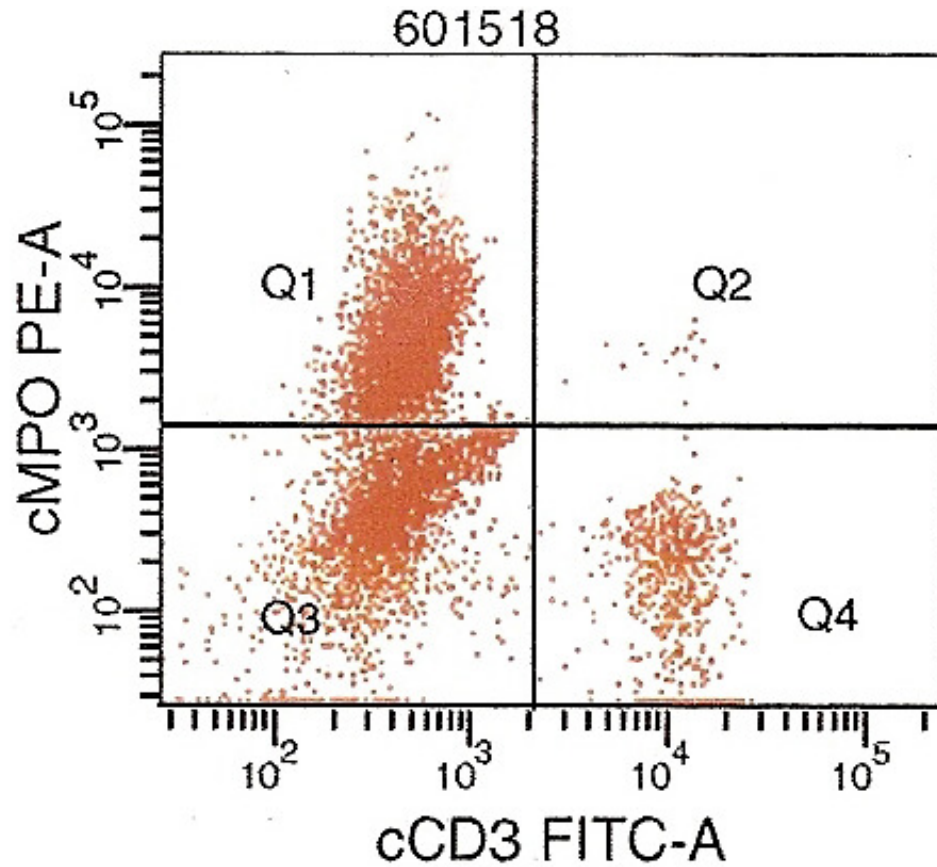


MPO/CD3 – CD79a/CD3

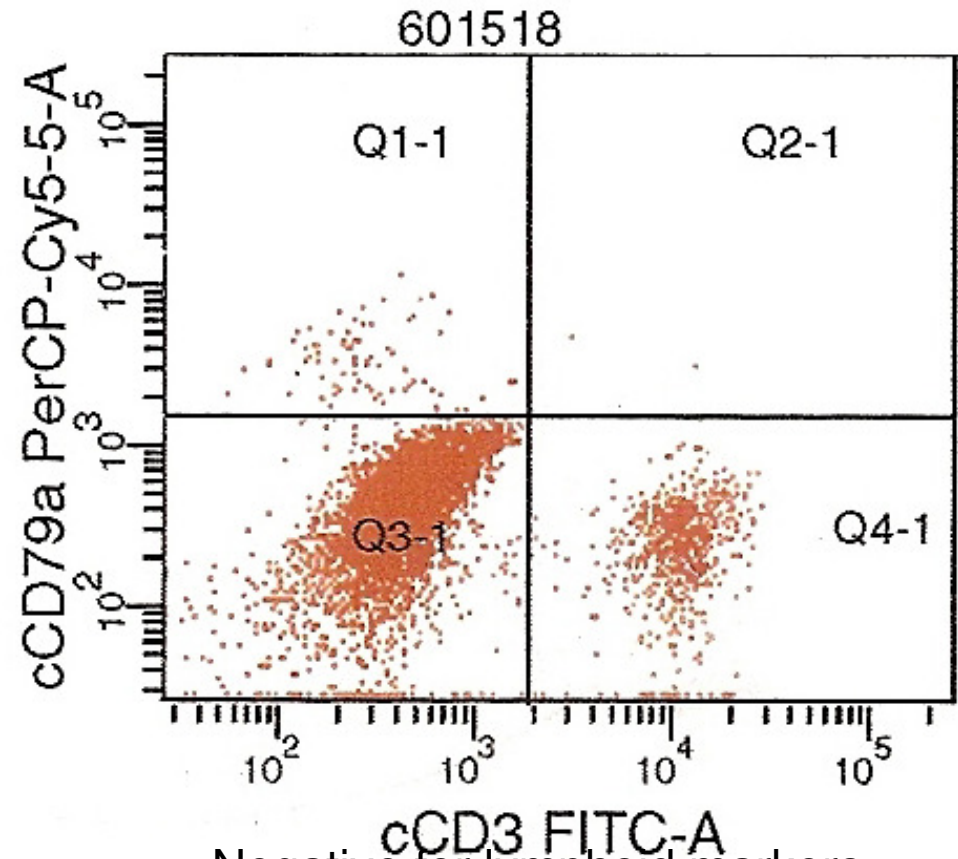


MPO/CD3 – CD79a/CD3

Myeloperoxidase
CD3 stains normal T-Lymphocytes



Distinct MPO positive population



Negative for lymphoid markers
CD79a and CD3

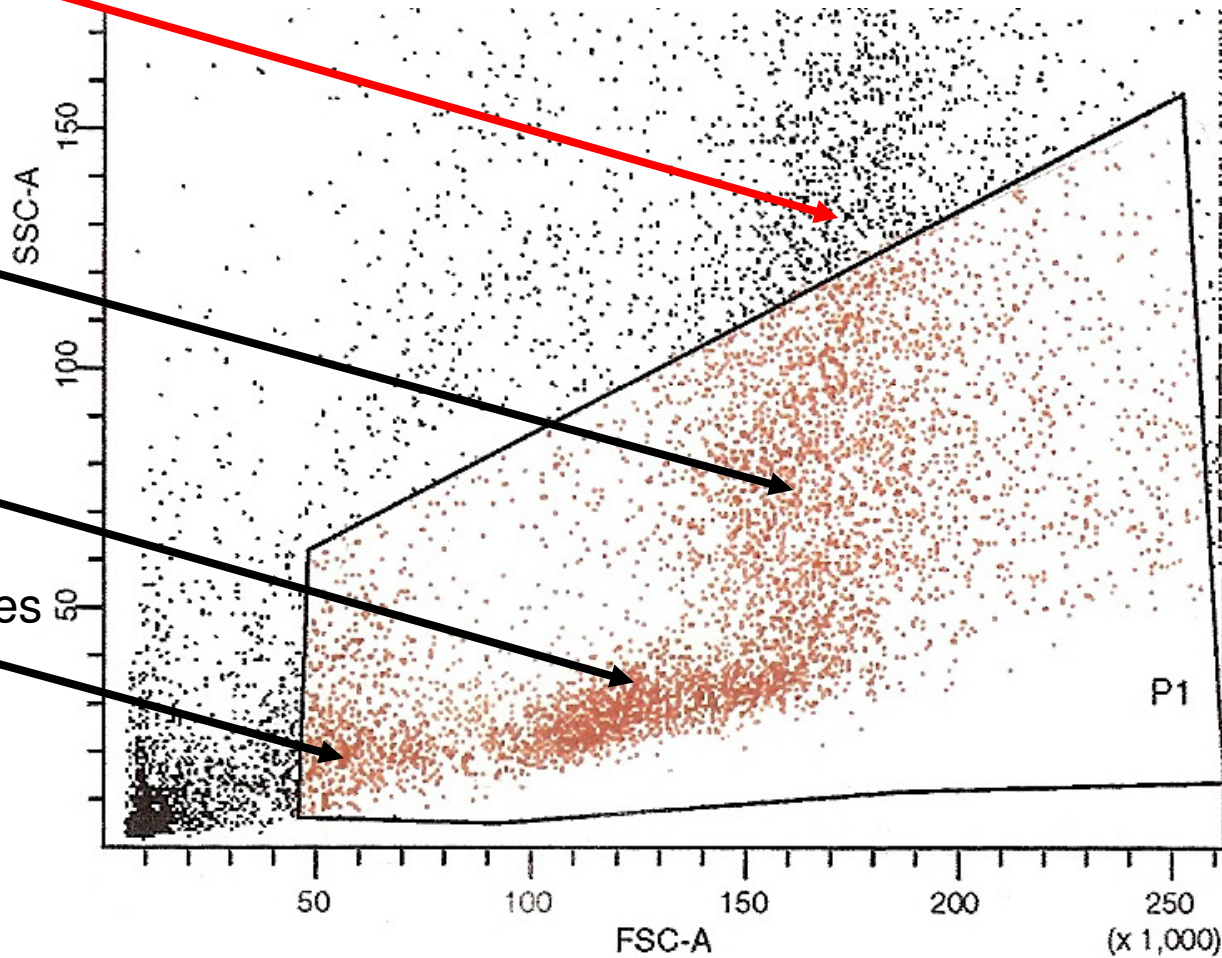
Scattergram I

Neutrophils

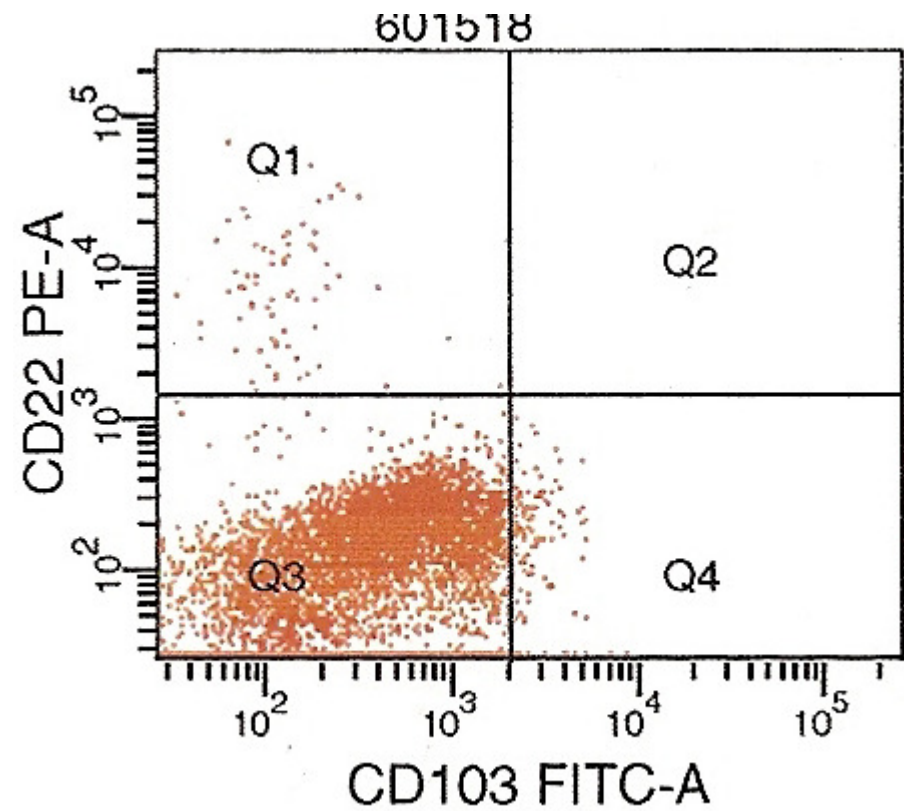
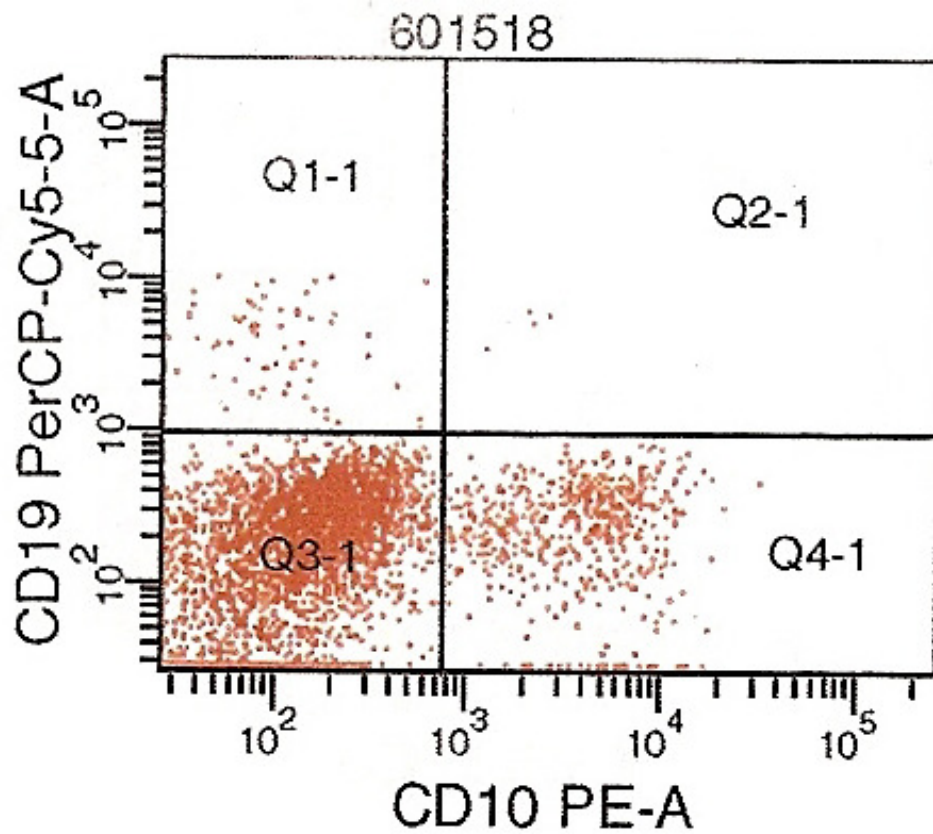
Myelocytes

Blasts

Lymphocytes



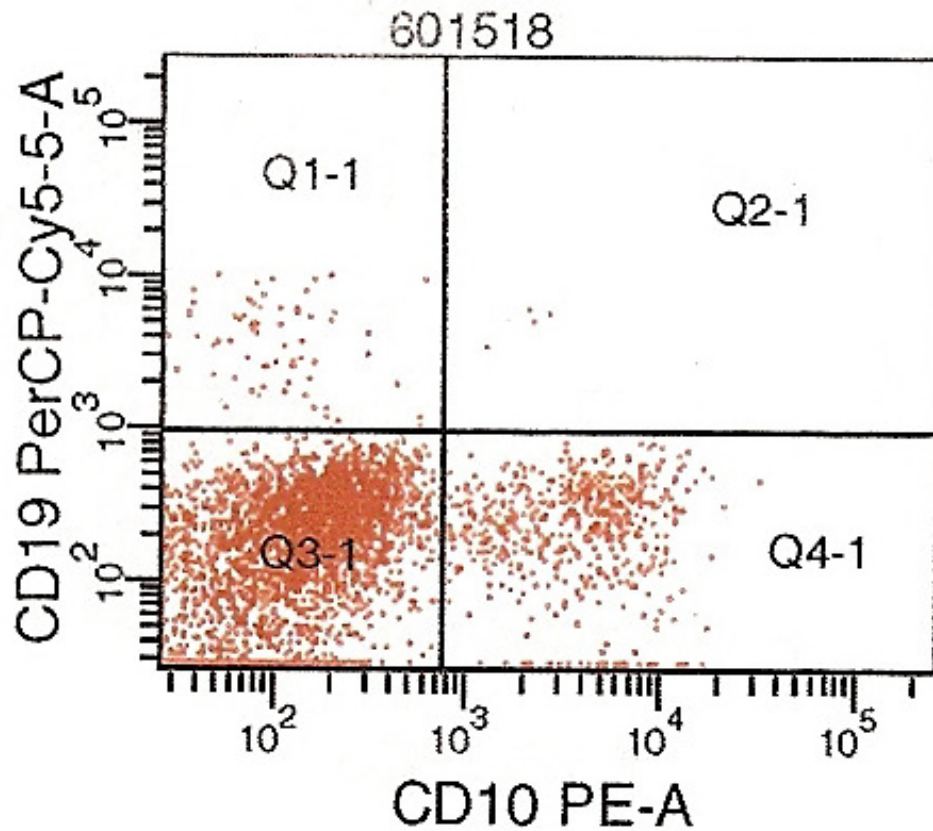
CD19/CD10 – CD22/CD103



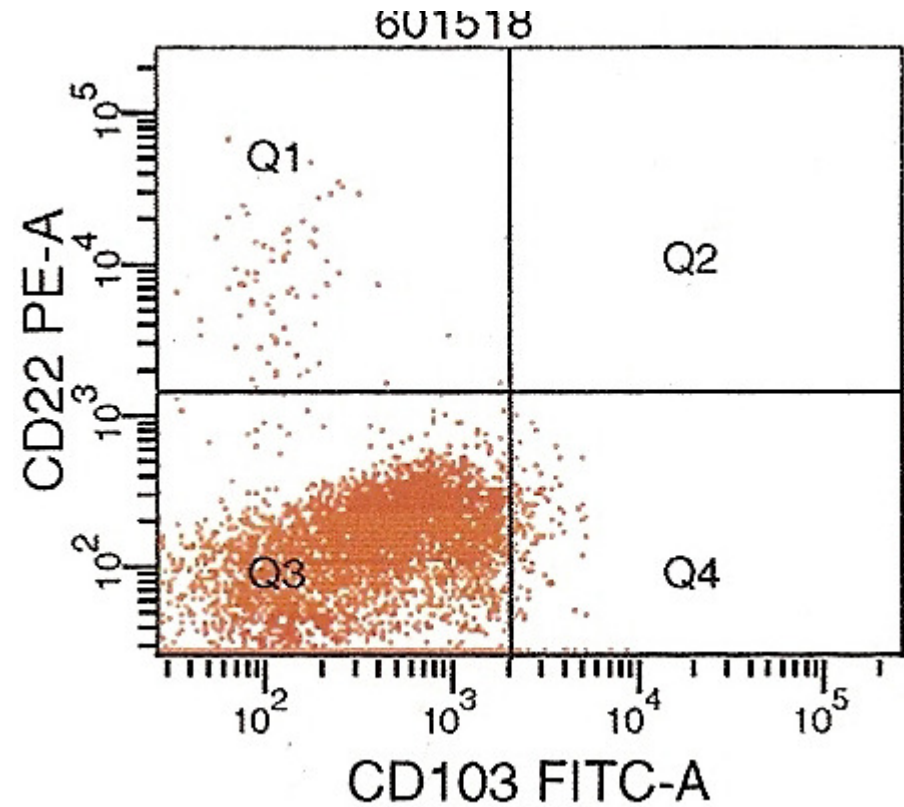
CD19/CD10 – CD22/CD103

B-lymphoid markers

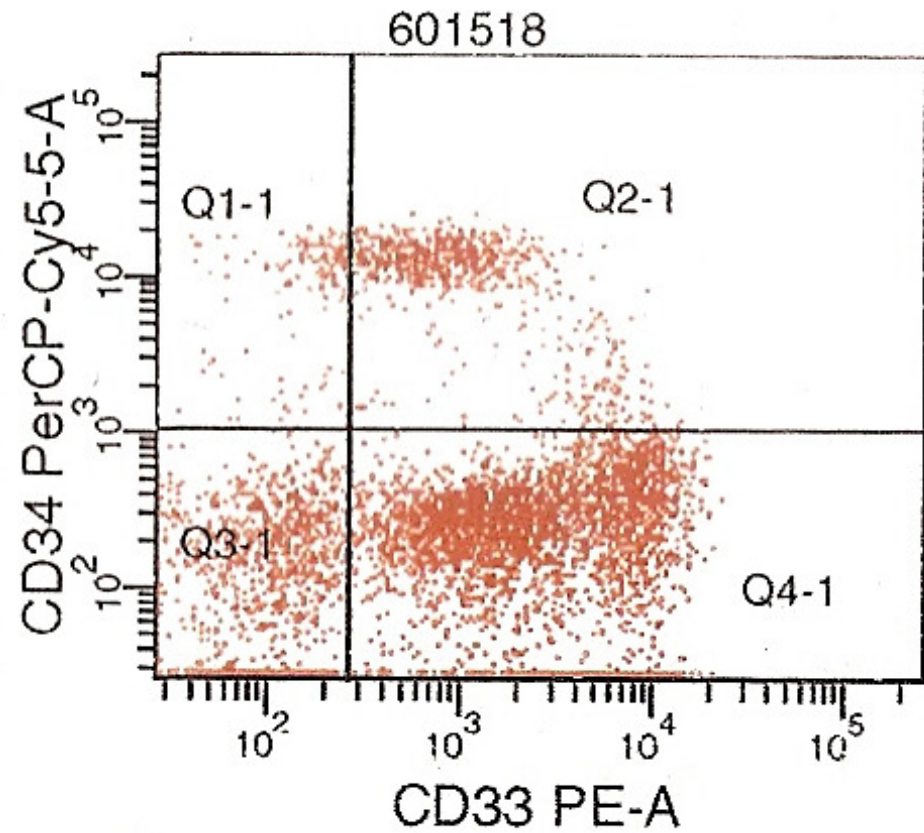
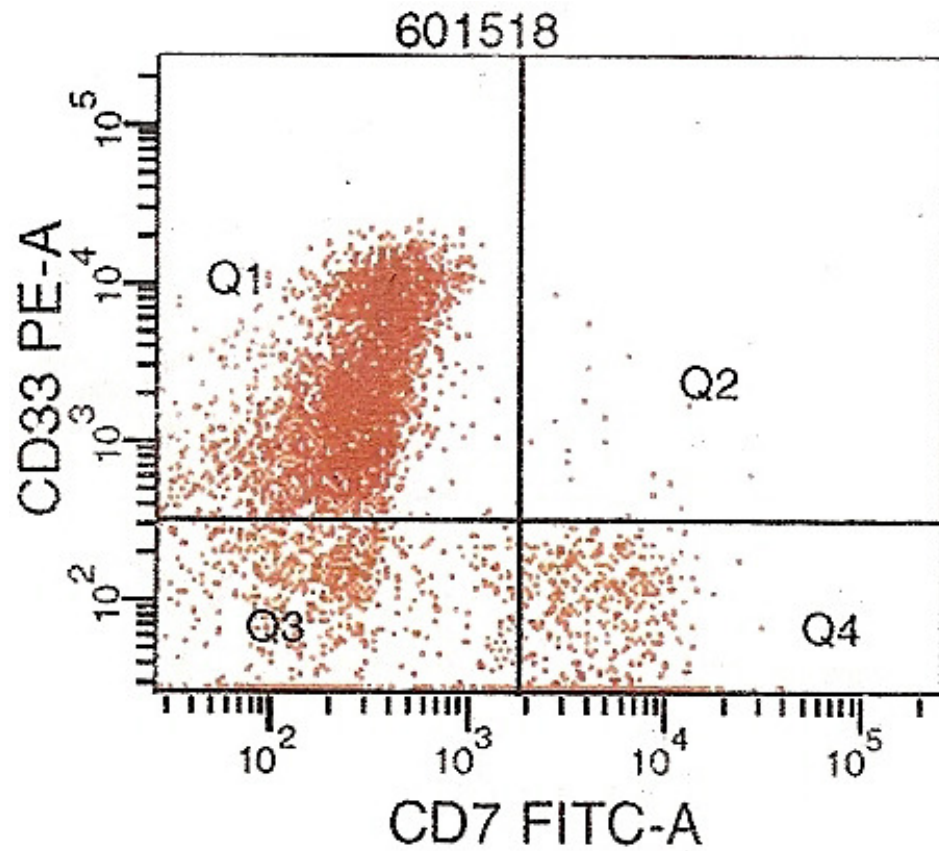
CD103 – Hairy Cell marker
(HCL causes monocytopenia)



B-lymphoid and HC markers negative



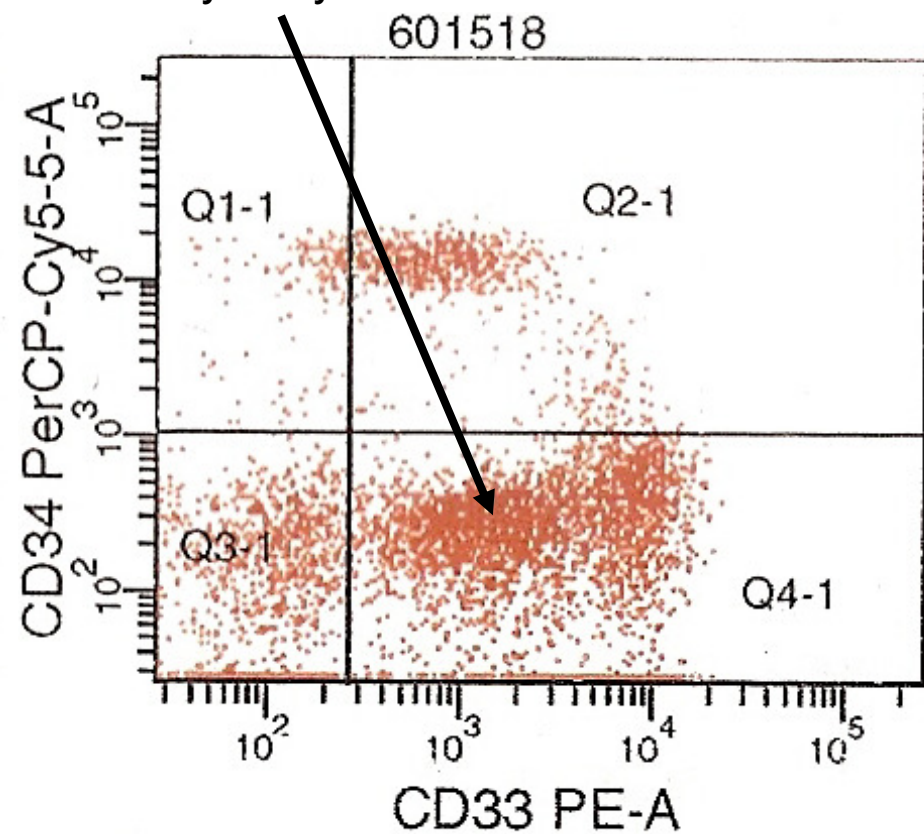
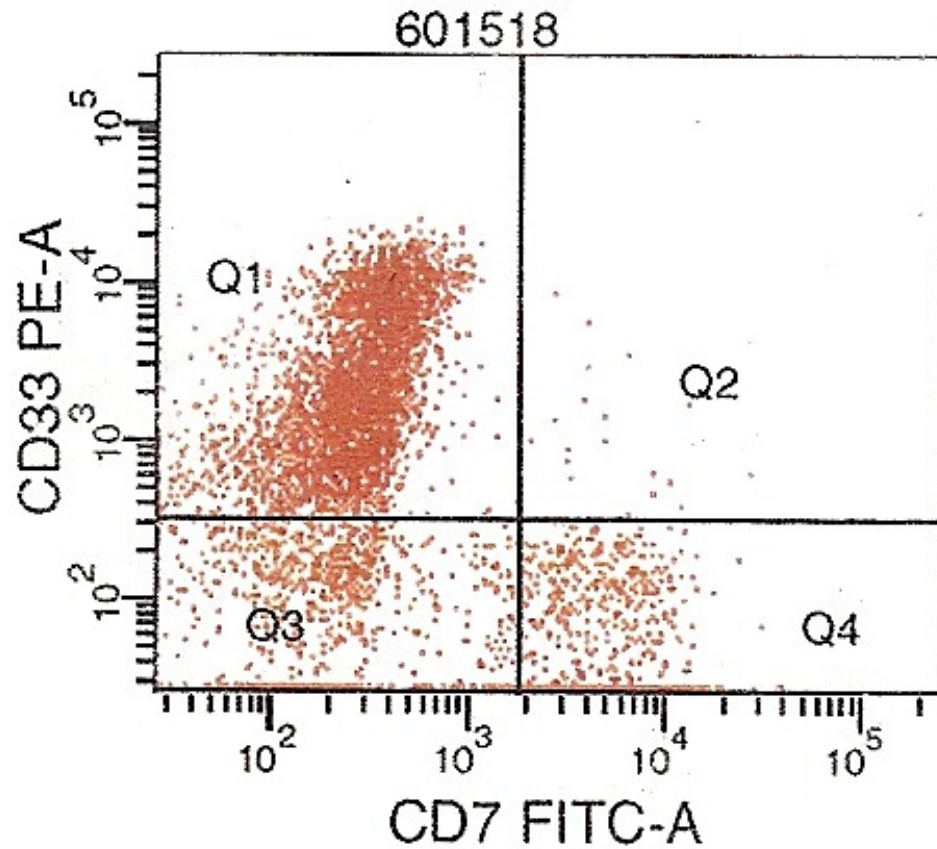
CD33/CD7 – CD34/CD33



CD33/CD7 – CD34/CD33

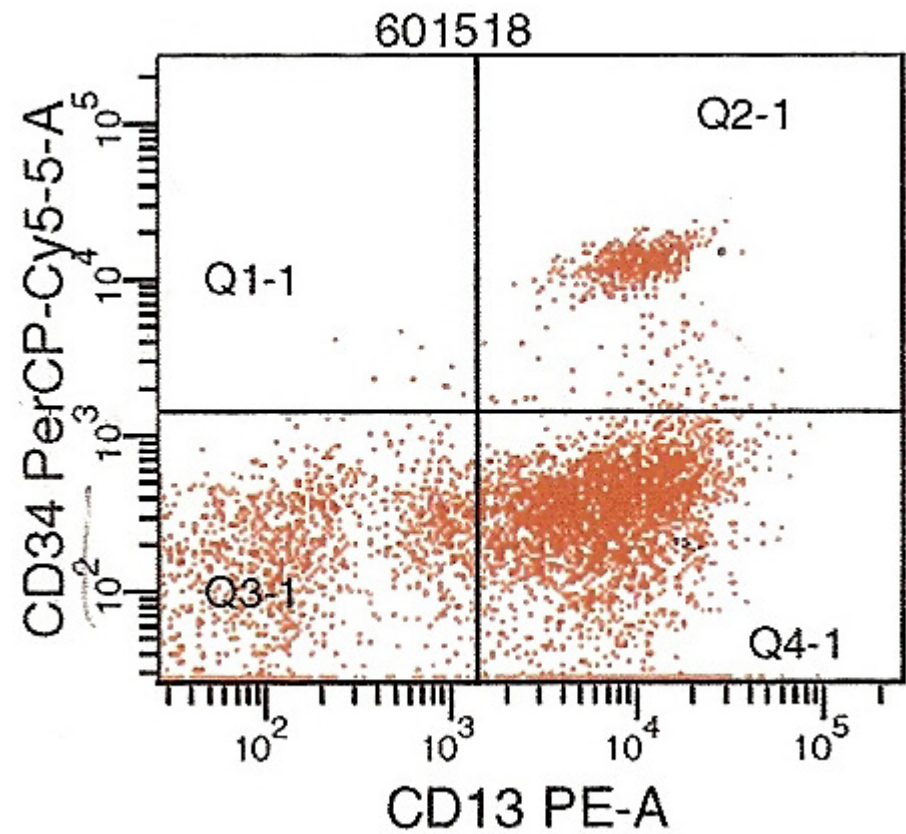
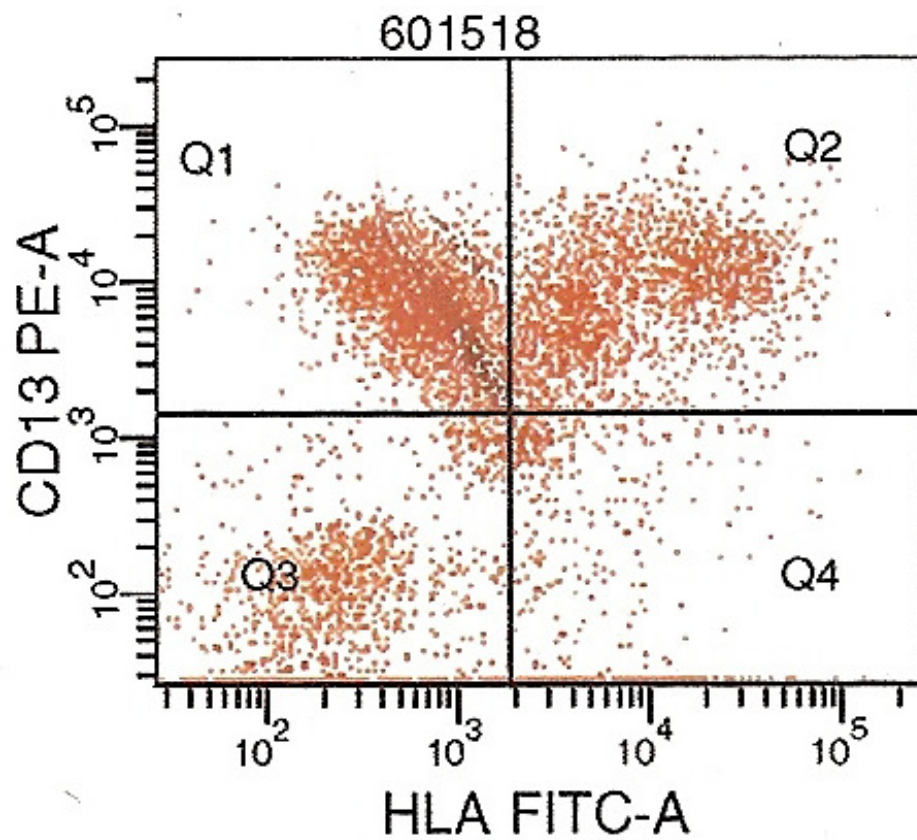
CD33 – myeloid marker

CD34 – immature cells
Leukaemic blasts or maturing
myelocytes?



Cells carry a myeloid marker, but are CD34 negative

CD13/HLA-DR – CD34/CD13

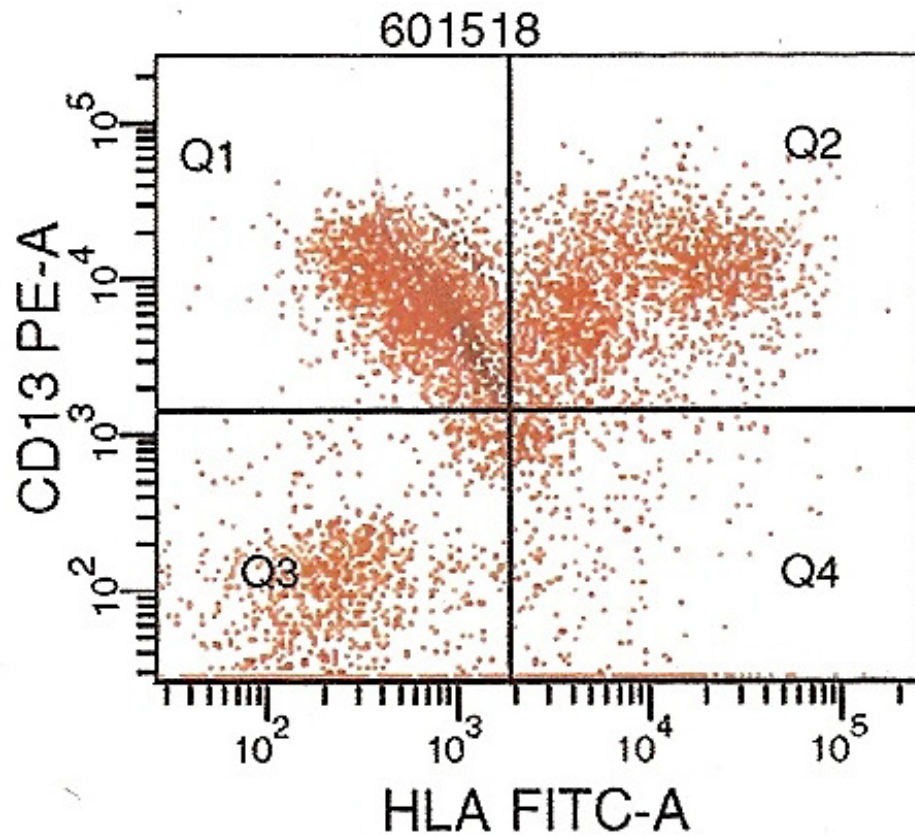


CD13/HLA-DR – CD34/CD13

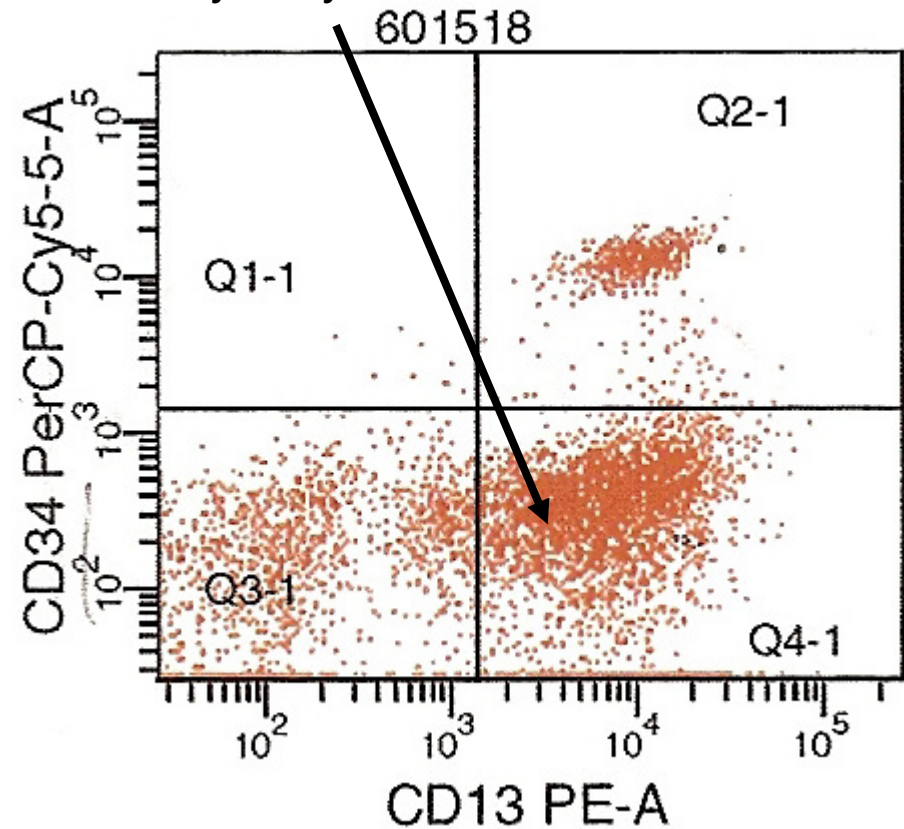
HLA – marker for immature cells

CD13 – myeloid marker

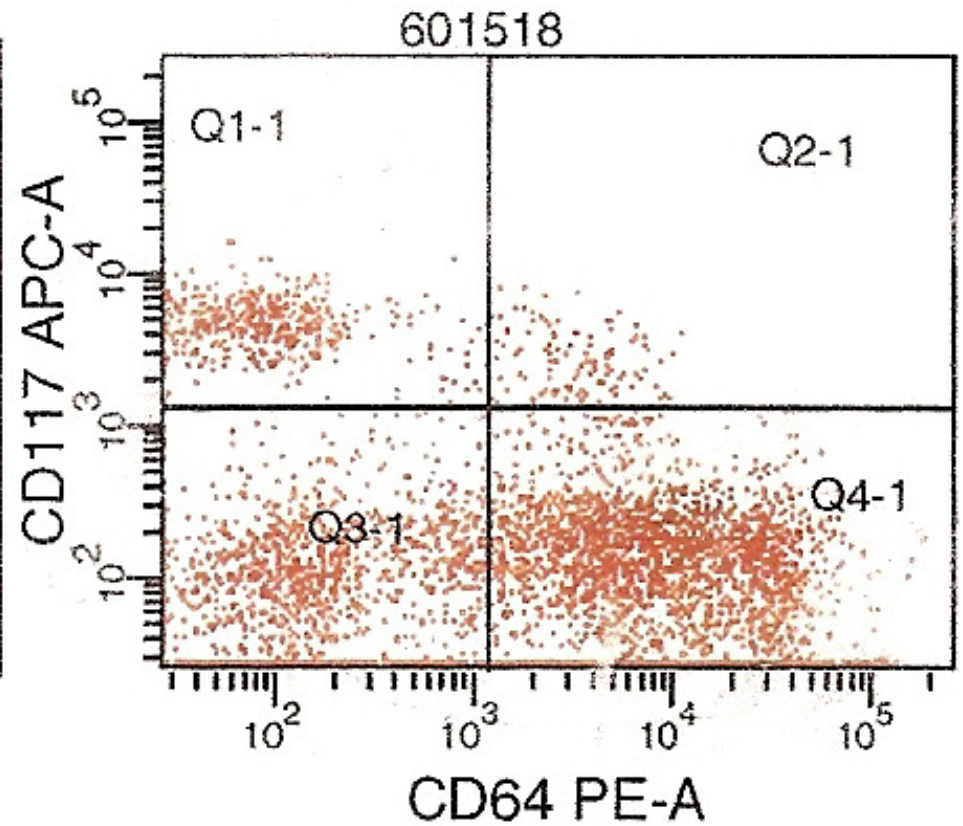
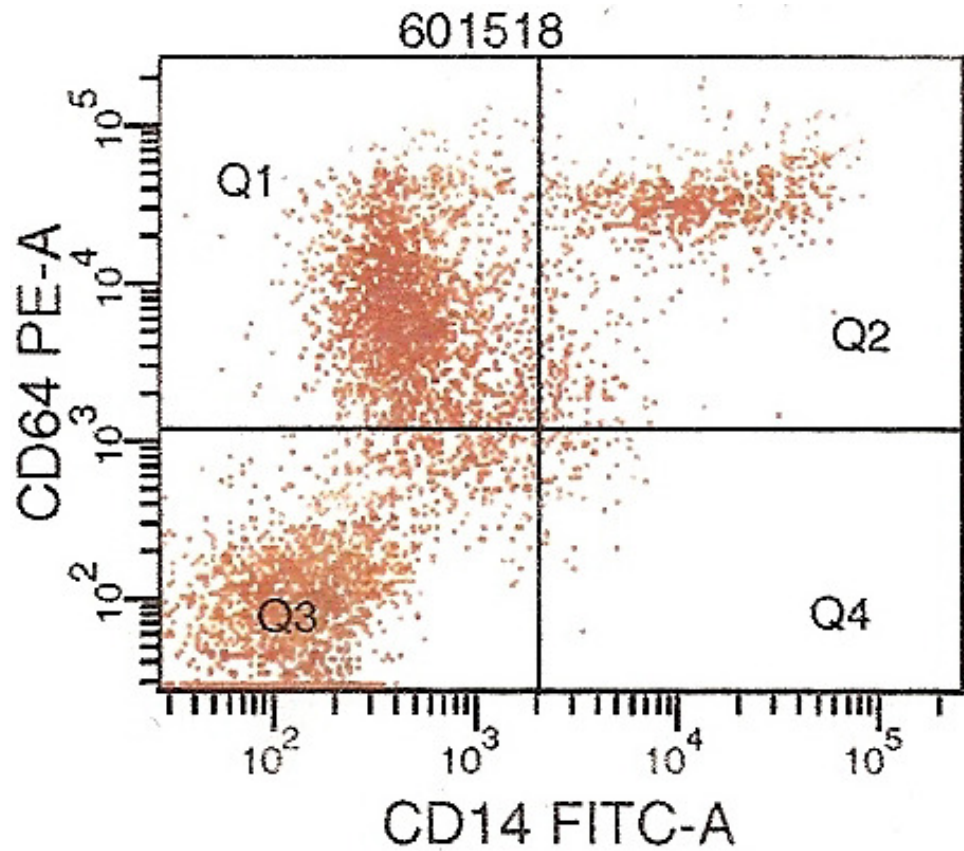
Leukaemic blasts or maturing myelocytes?



CD13 positive cells



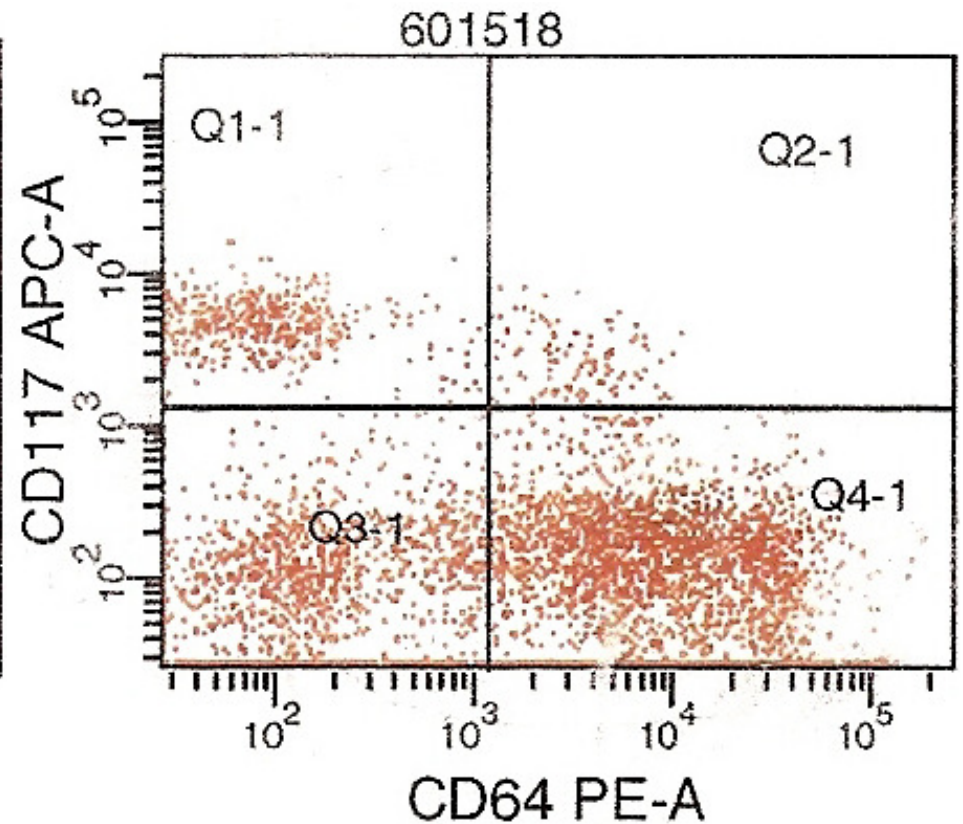
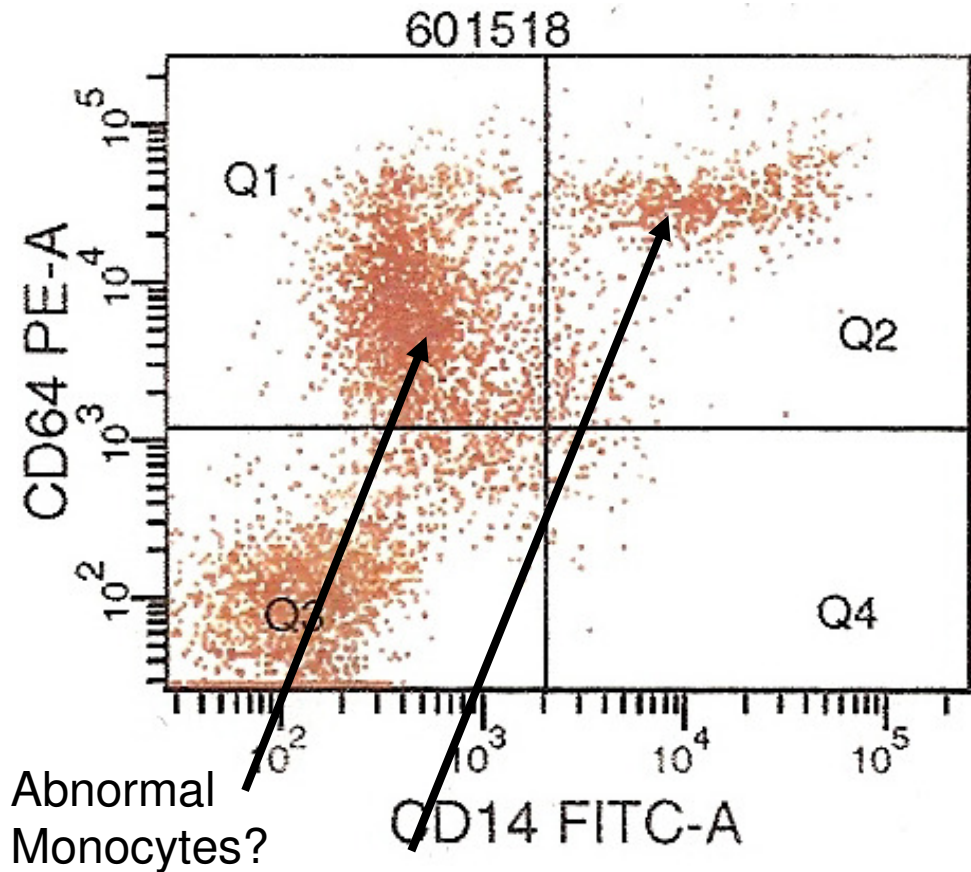
CD64/CD14 – CD117/CD64



CD64/CD14 – CD117/CD64

CD14 – unspecific myeloid marker
CD64 – monocytoid differentiation

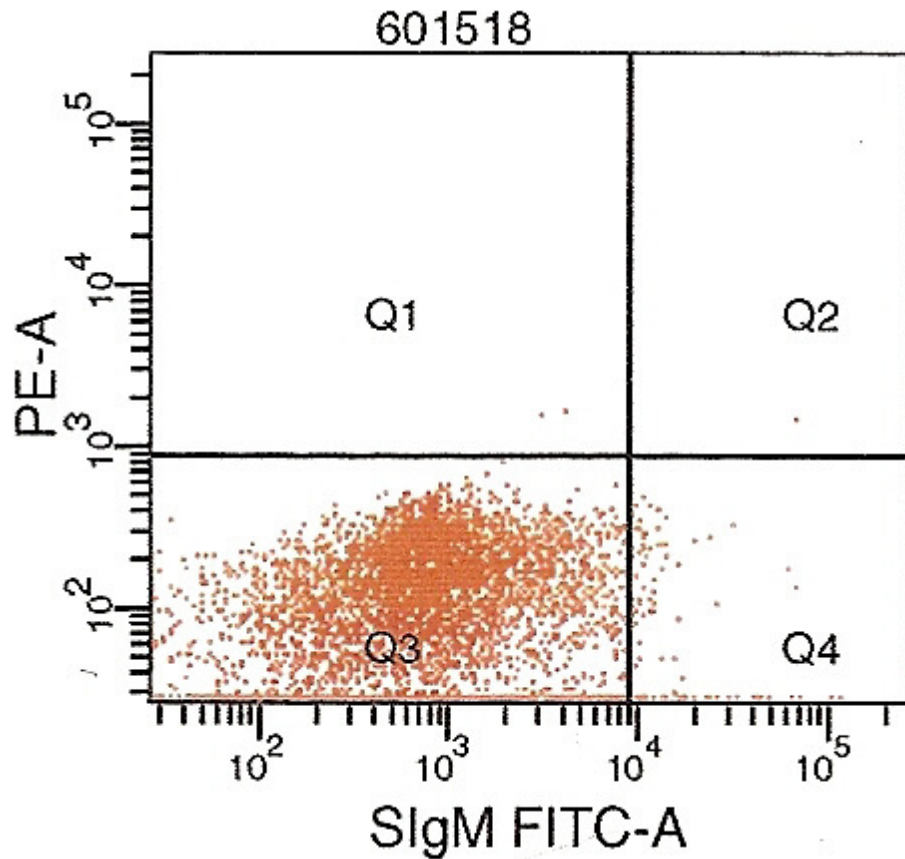
CD117 – immature cells



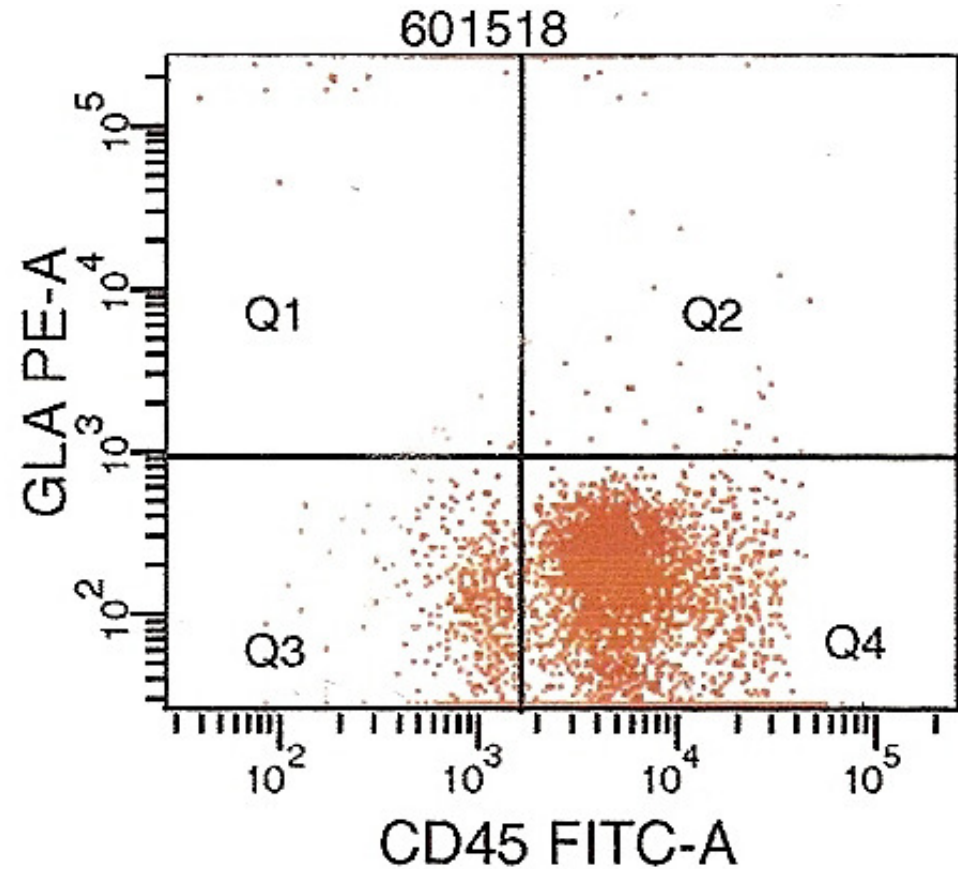
CD64/CD14 positive cells are normal monocytes

CD64 positive /CD117 negative cells

Surface IgM – CD45

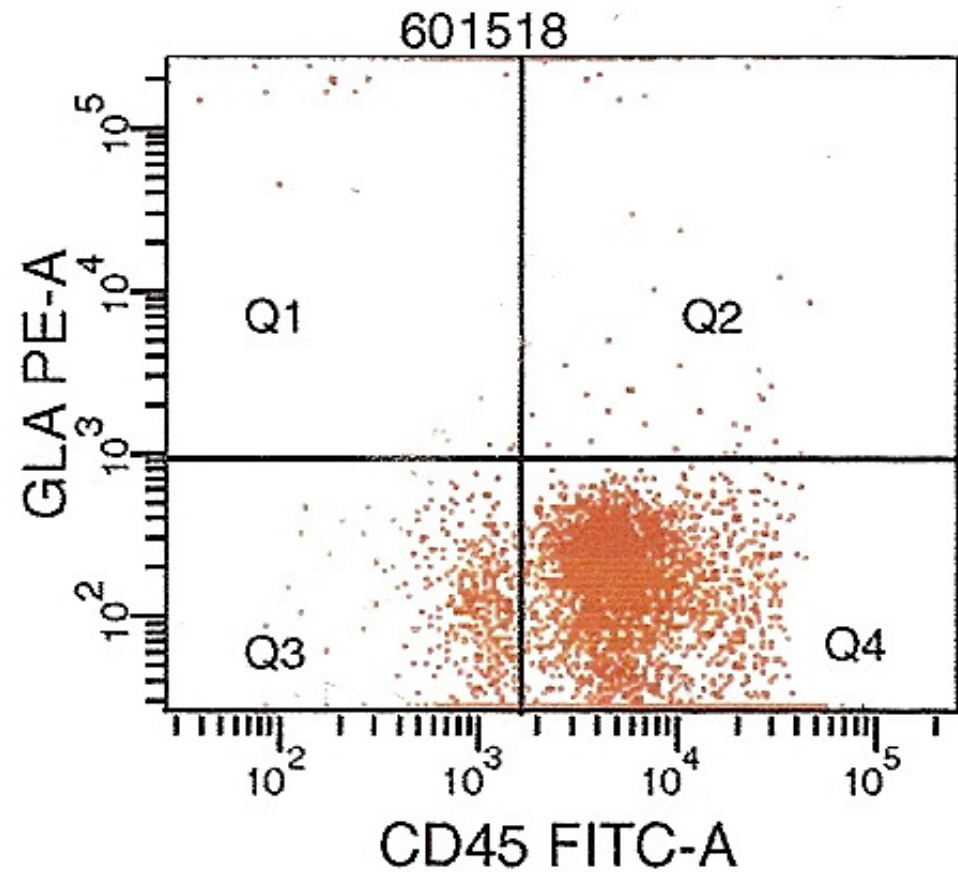
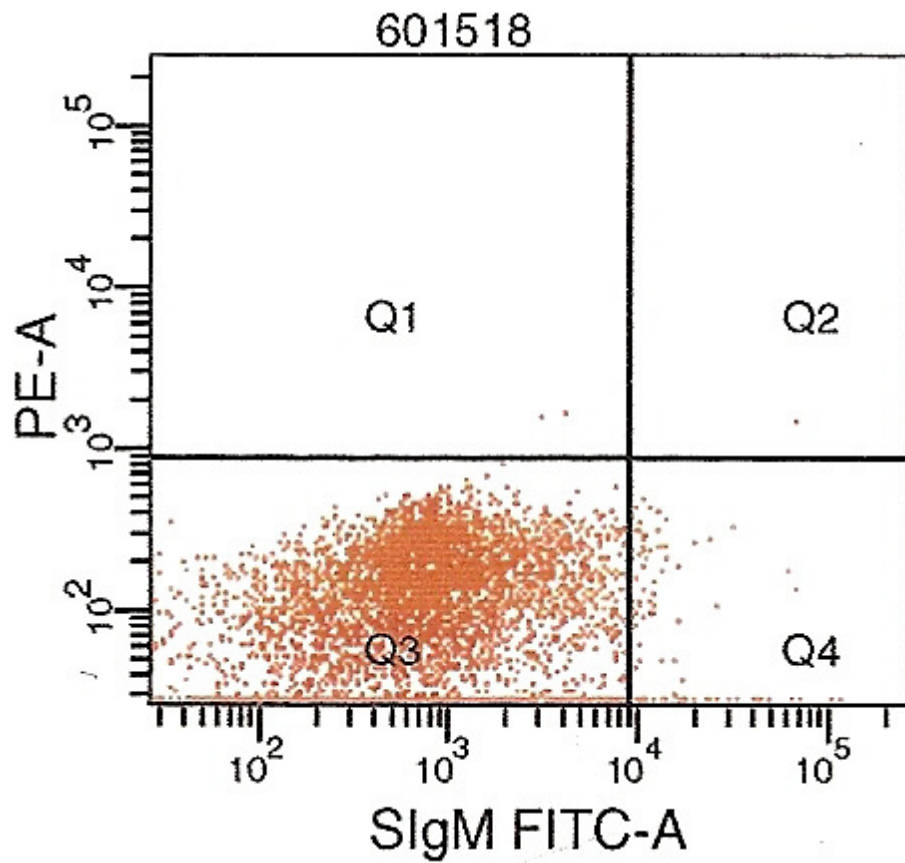


Cells do not carry IgM

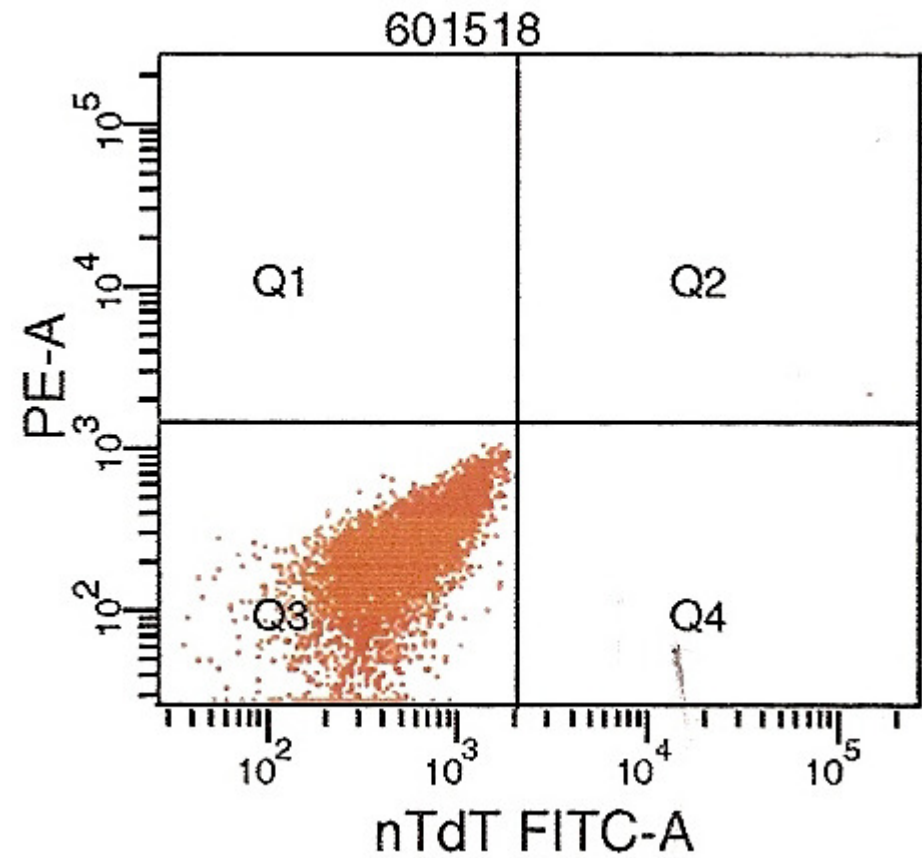
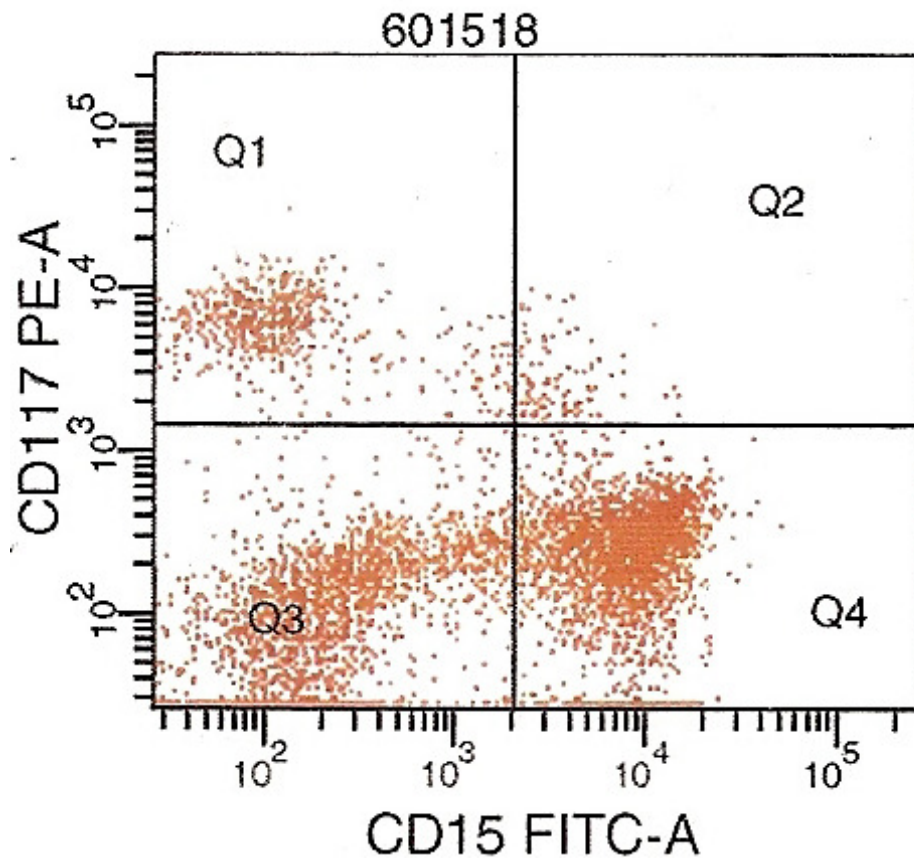


Cells are all CD45 positive – rules out a non haematopoietic tumour

Surface IgM – CD45

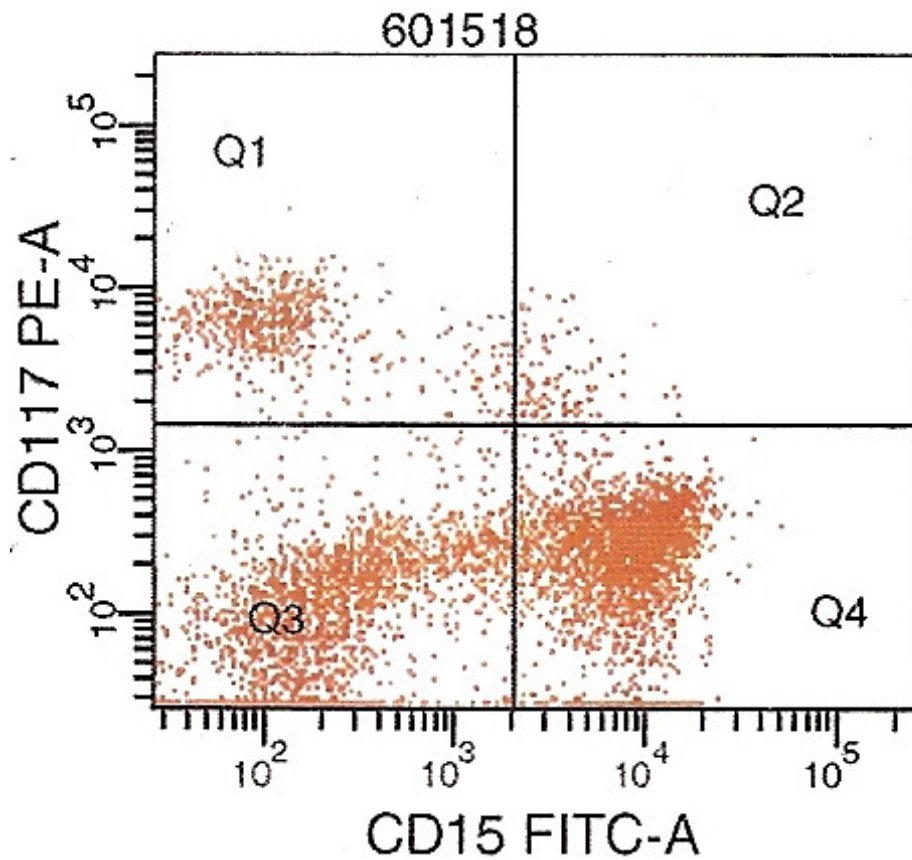


CD117/CD15 - TdT

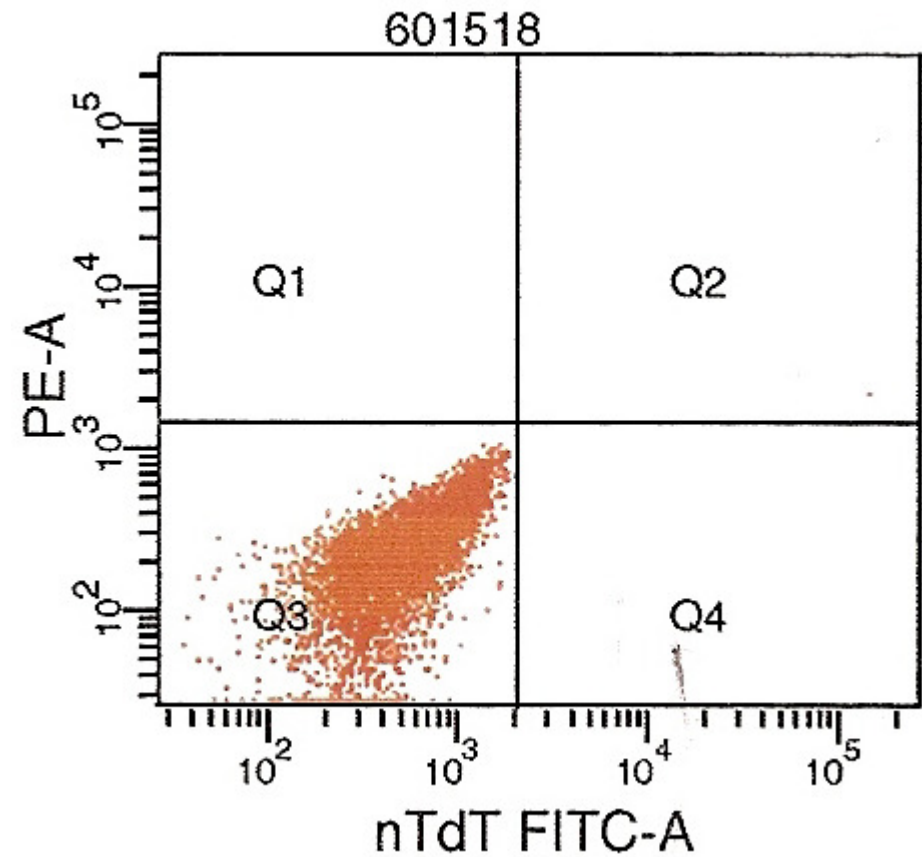


CD117/CD15 - TdT

CD15 – monocytoid marker



Asynchronous expression of monocytoid marker



Cells are TdT neagtive

Flowcytometry

T-LYMPHOID MARKERS

Cell Marker - CD2	30	%
Cell Marker - cCD3	10	%
Cell Marker - CD5	32	%
Cell Marker - CD7	13	%

B-LYMPHOID MARKERS

Cell Marker - CD10	<1	%
Cell Marker - CD19	2	%
Cell Marker - CD20	2	%
Cell Marker - CD22	1	%
Cell Marker - cCD79a	1	%
Cell Marker - sIgM	2	%

IMMATURE STEM CELL MARKERS

Cell Marker - CD117	14	%
Cell Marker - nTdT	NEG	
Cell Marker - CD34	14	%

DOUBLE CELL MARKERS

Cell Marker - CD7:CD33	<1	%
------------------------	----	---

OTHERS

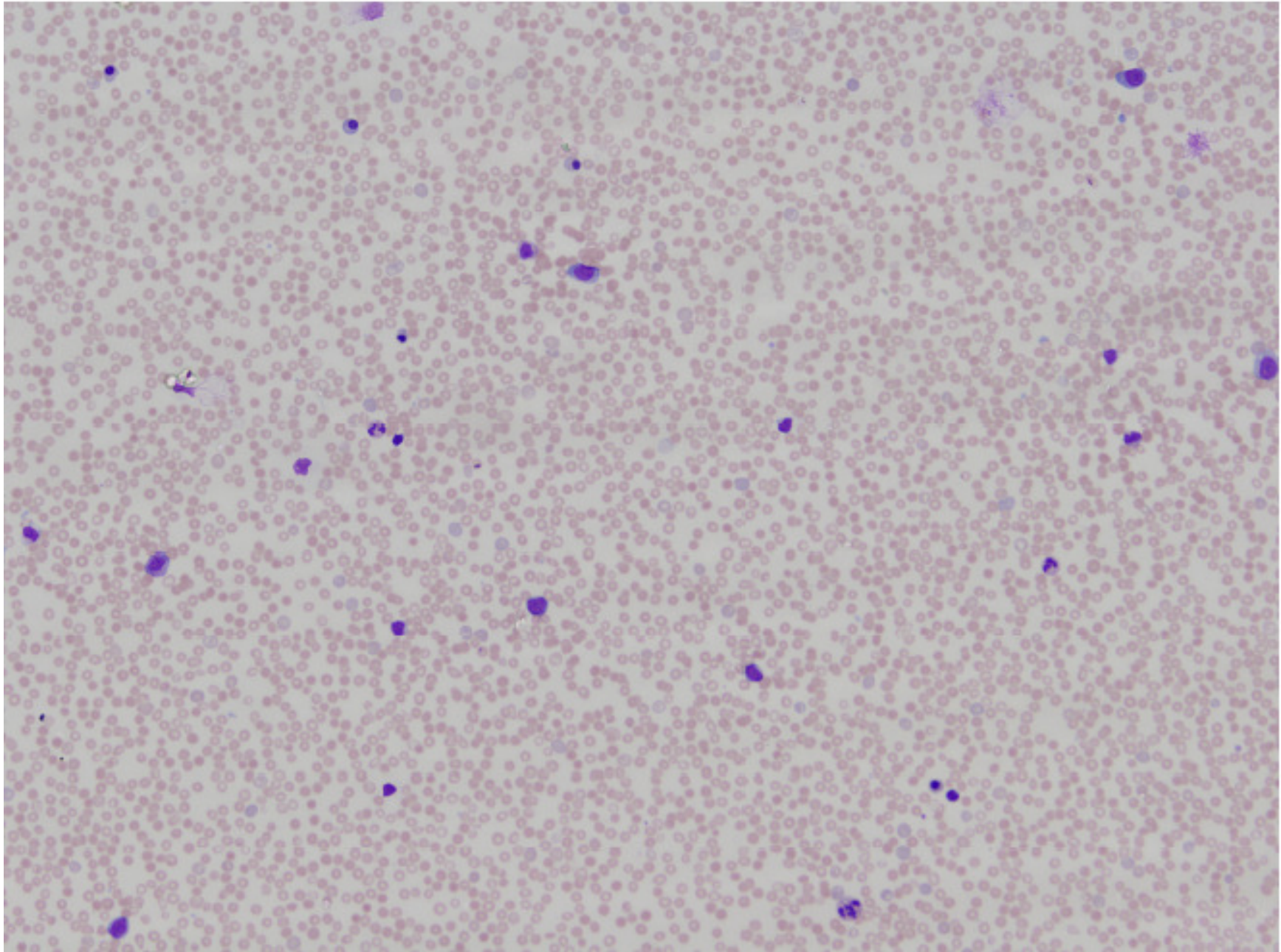
Cell Marker - CD45	86	%
--------------------	----	---

Cell Marker - HLA-DR	41	%
----------------------	----	---

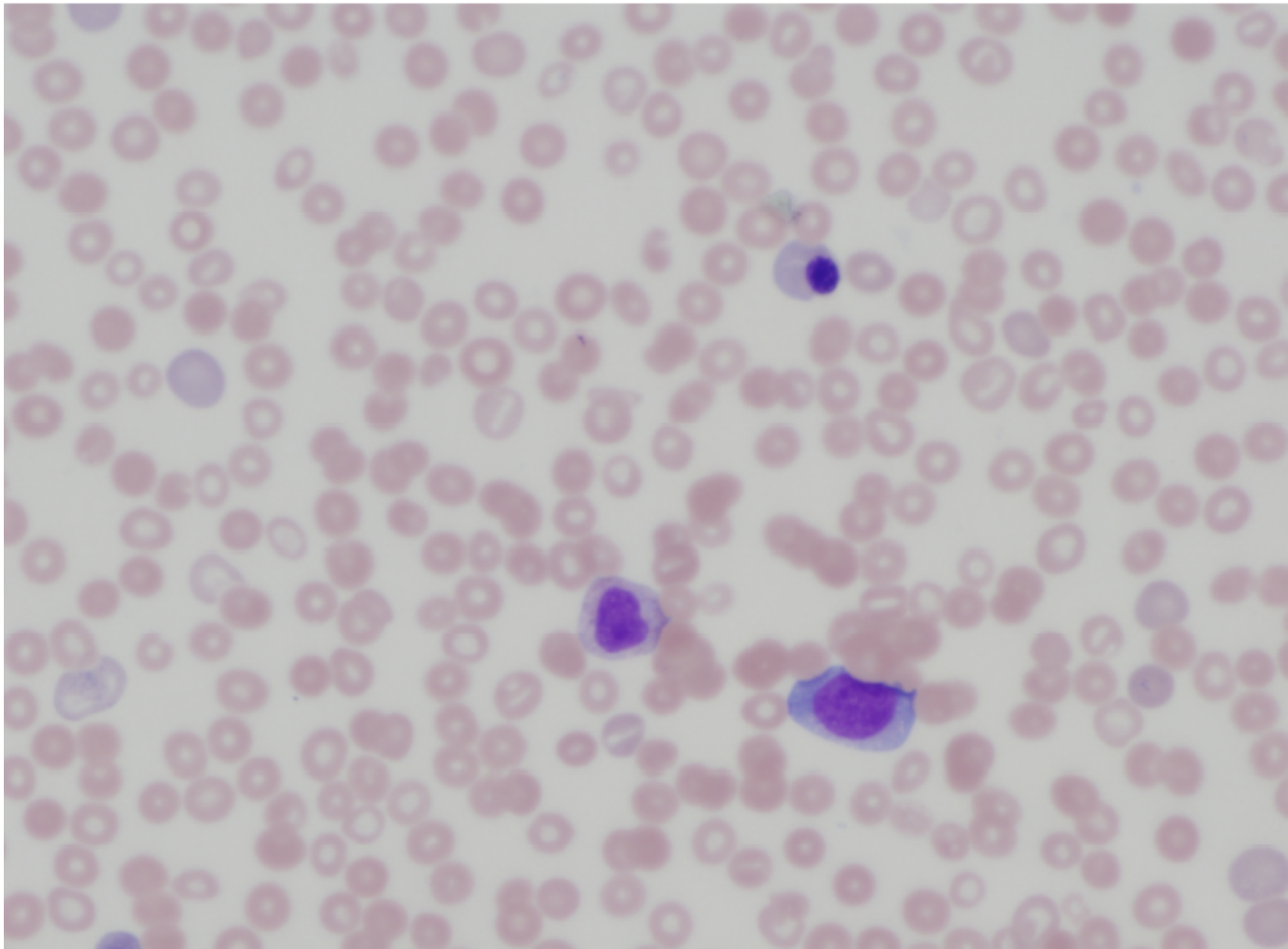
MYELOID MARKERS

Cell Marker - CD13	69
Cell Marker - CD14	14
Cell Marker - CD15	50
Cell Marker - CD33	72
Cell Marker - cMPO	52
Cell Marker - CD64	55
Cell Marker - Glycophorin A	5
Cell Marker - CD41A	7

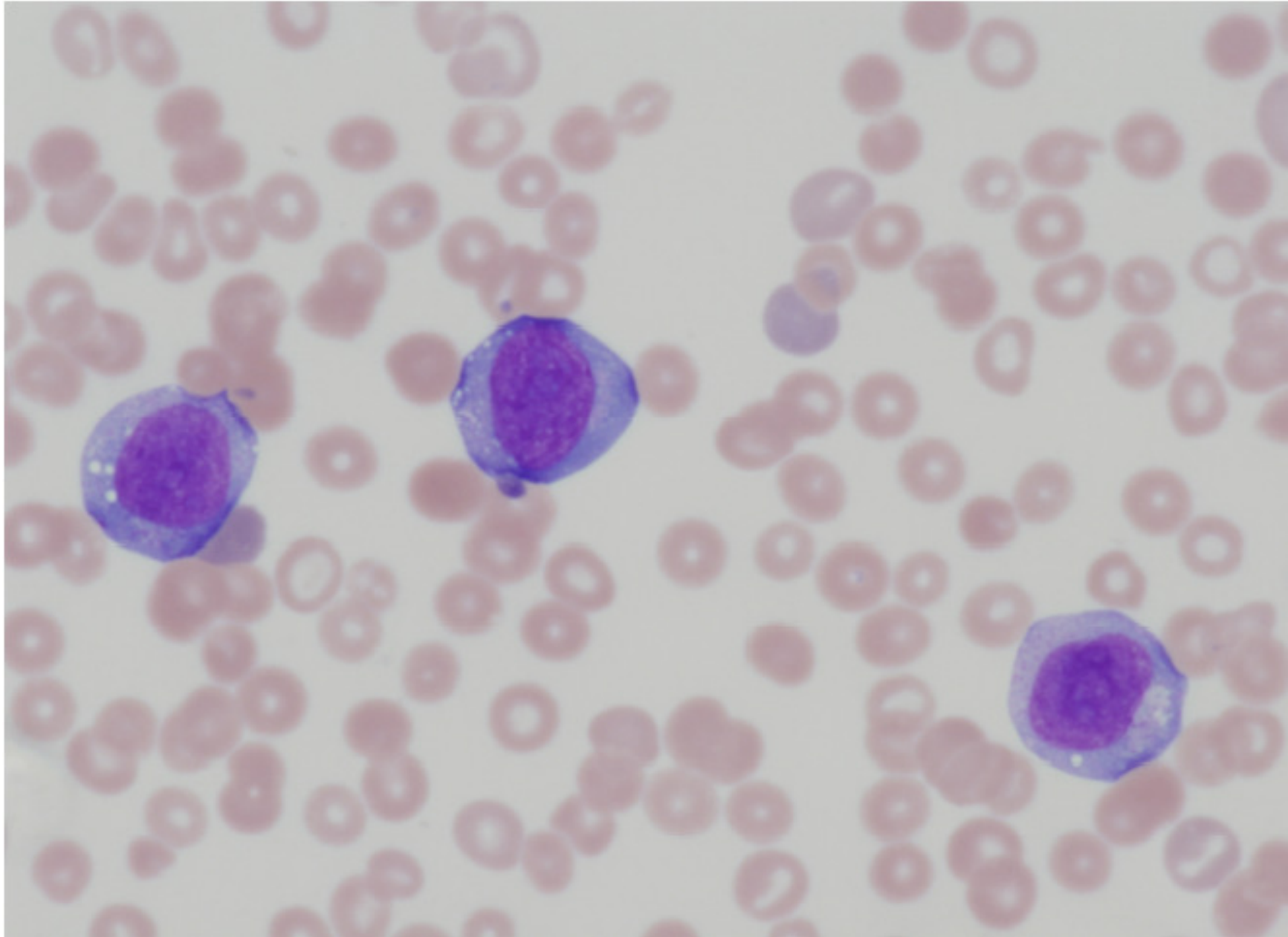
Blood Film I



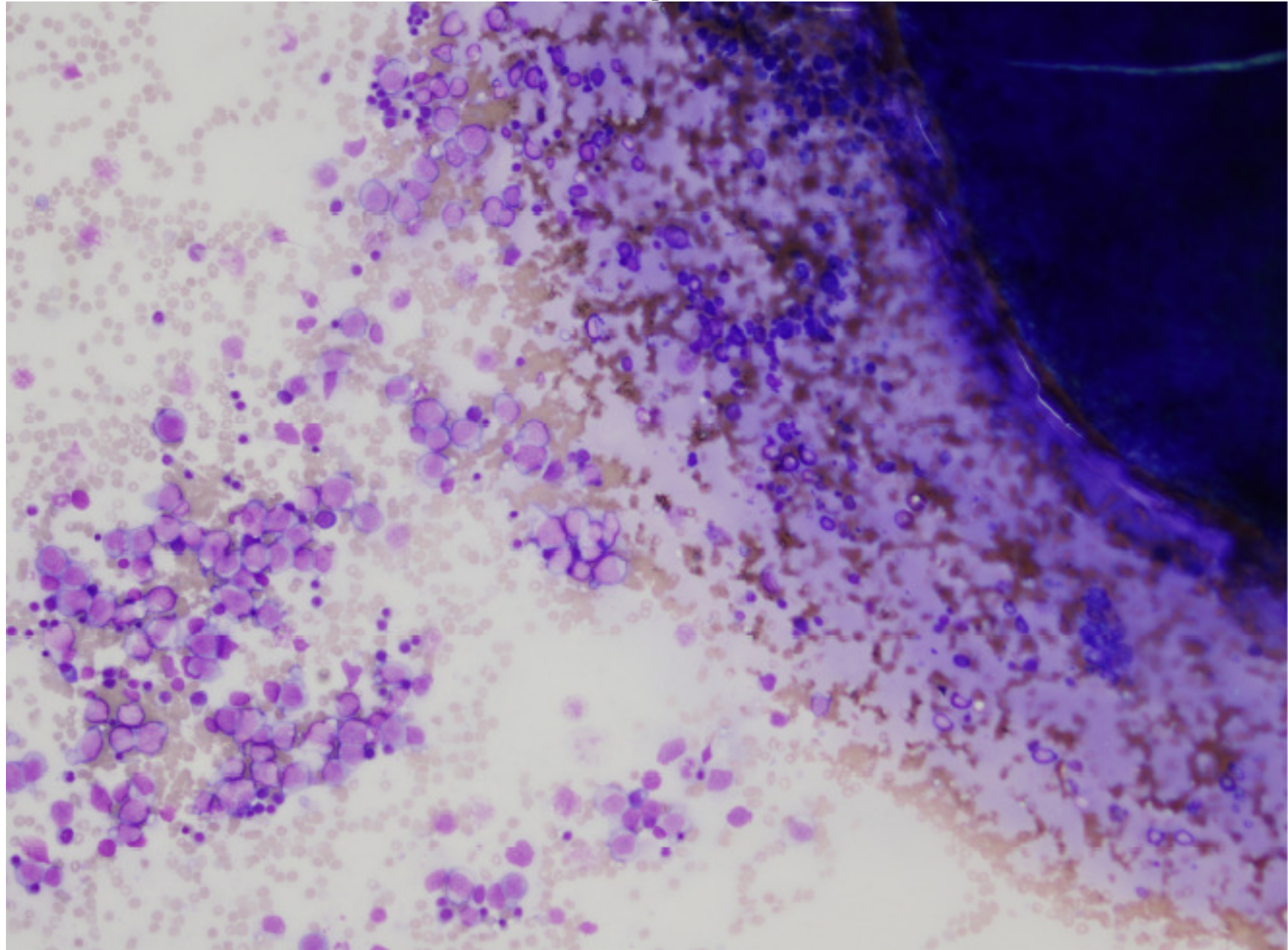
Blood Film II



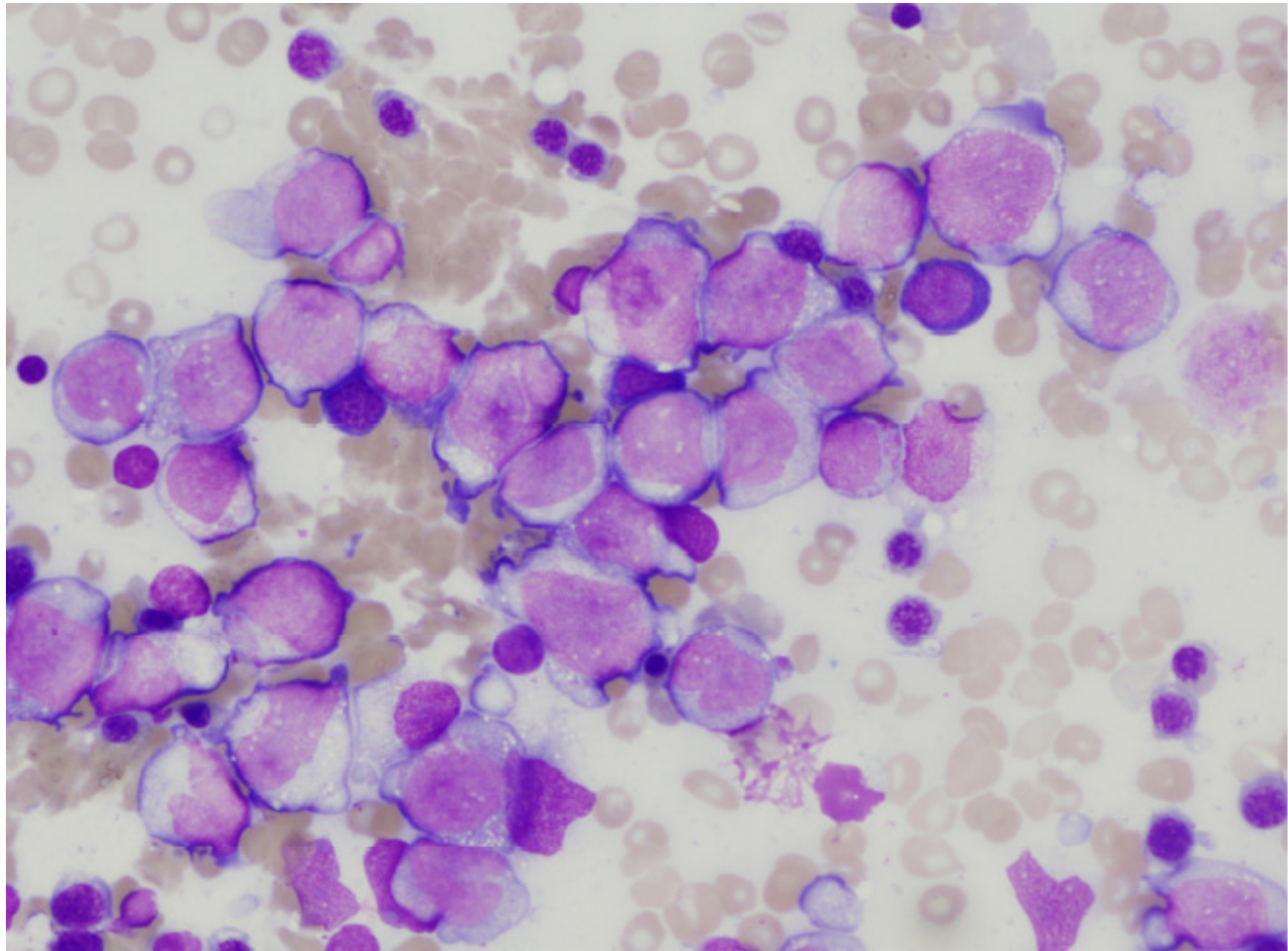
Blood Film III



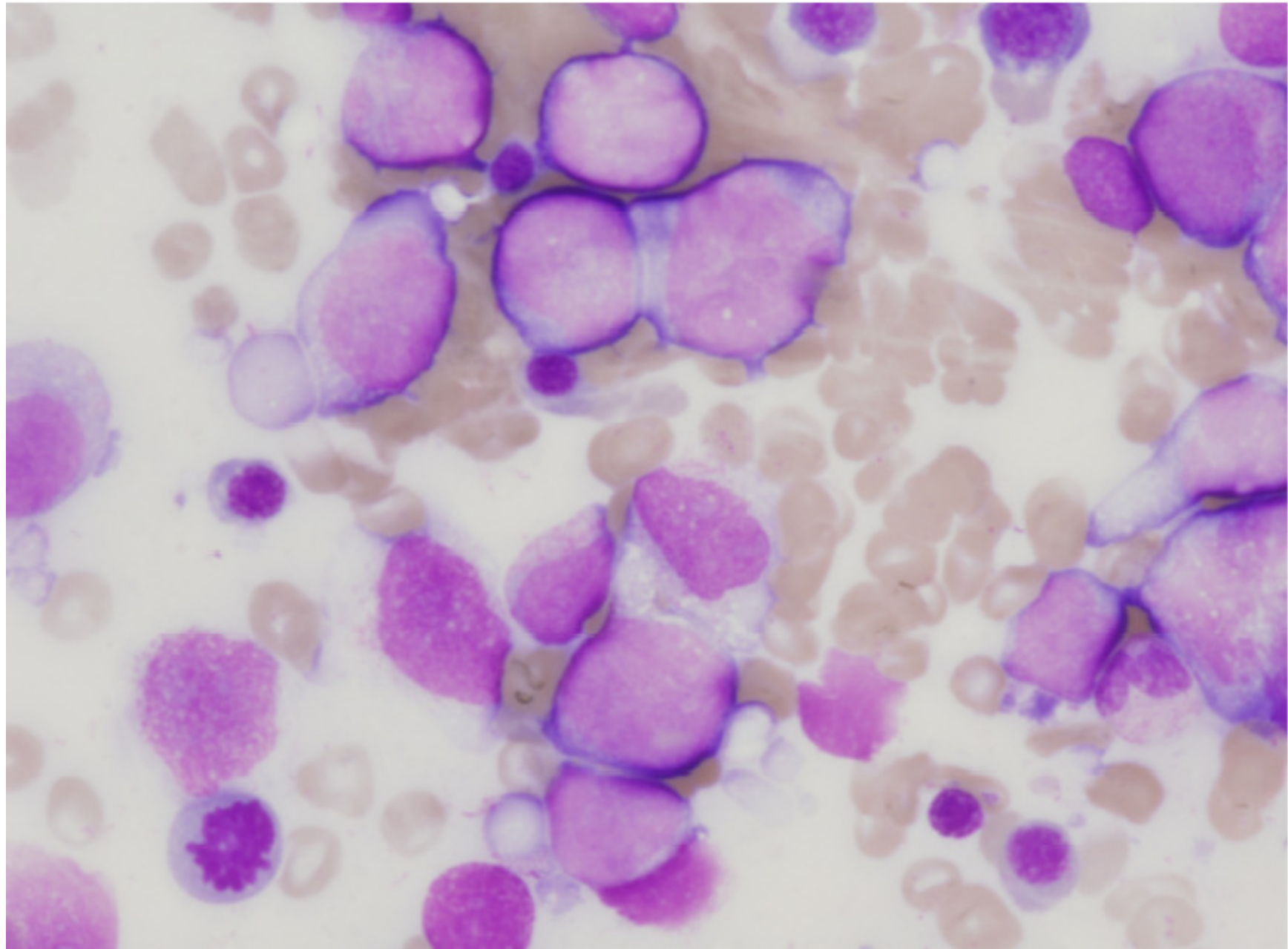
Bone Marrow aspirate H&E x100



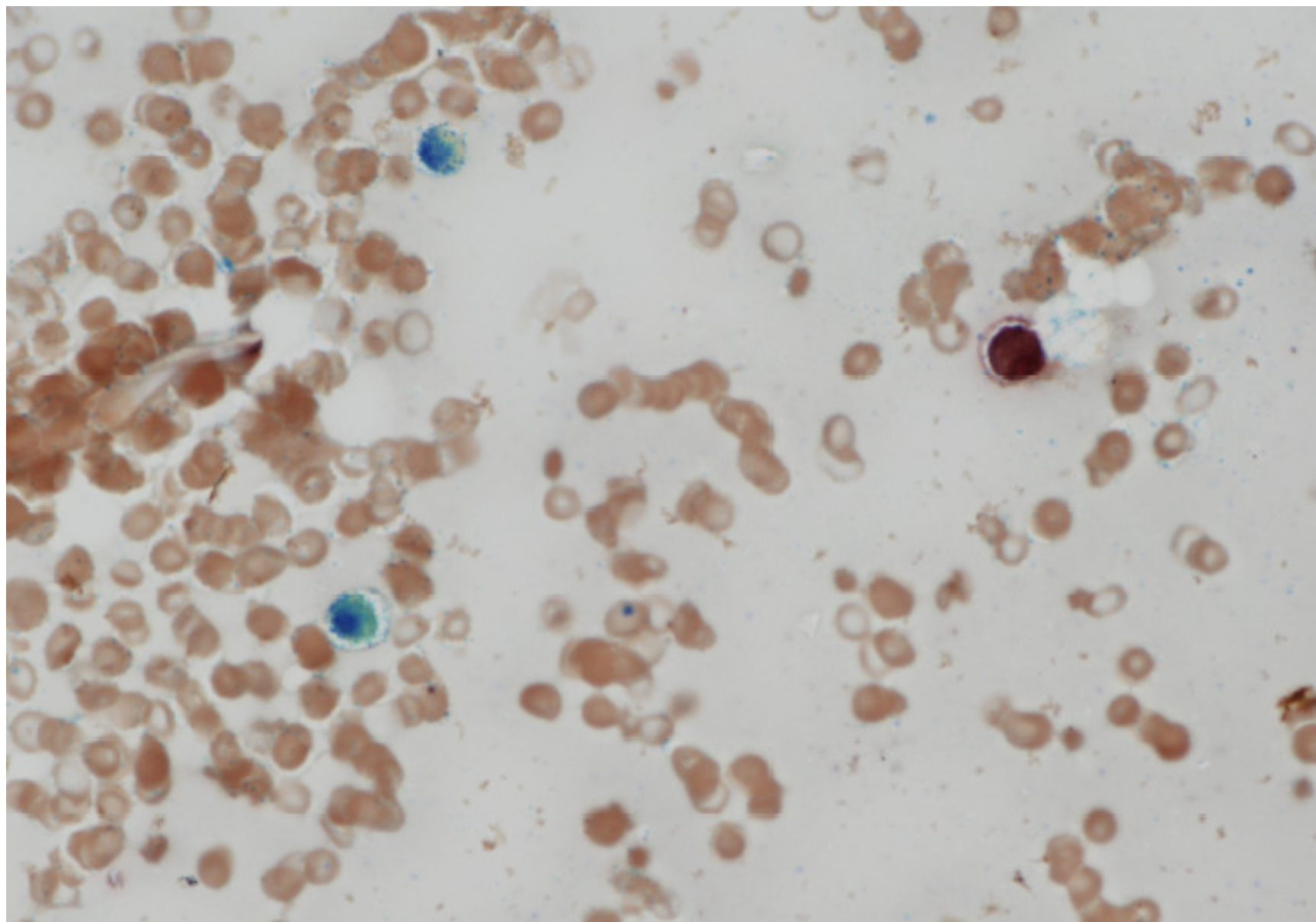
Bone Marrow aspirate H&E x400



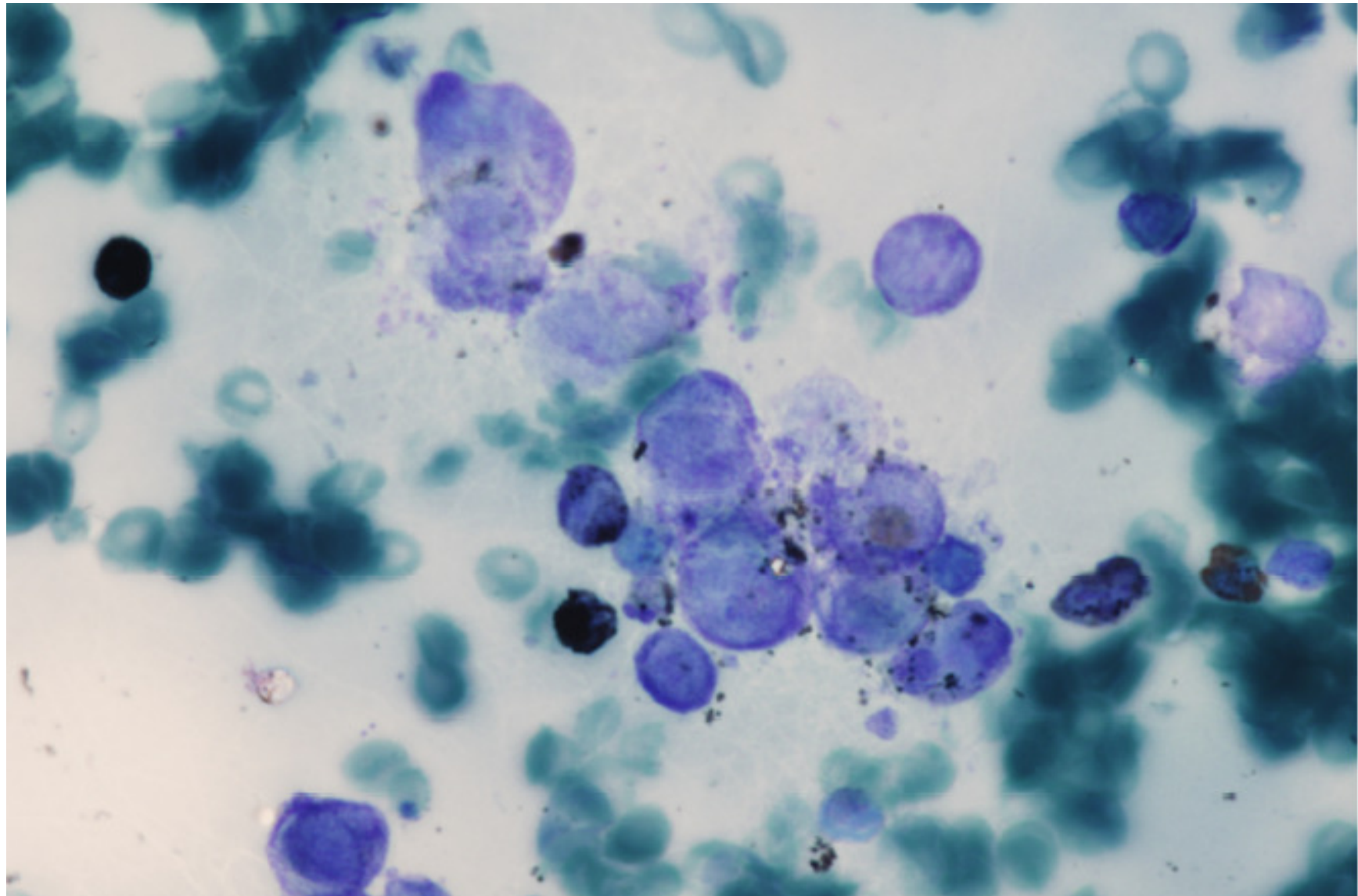
Bone Marrow aspirate H&E x600



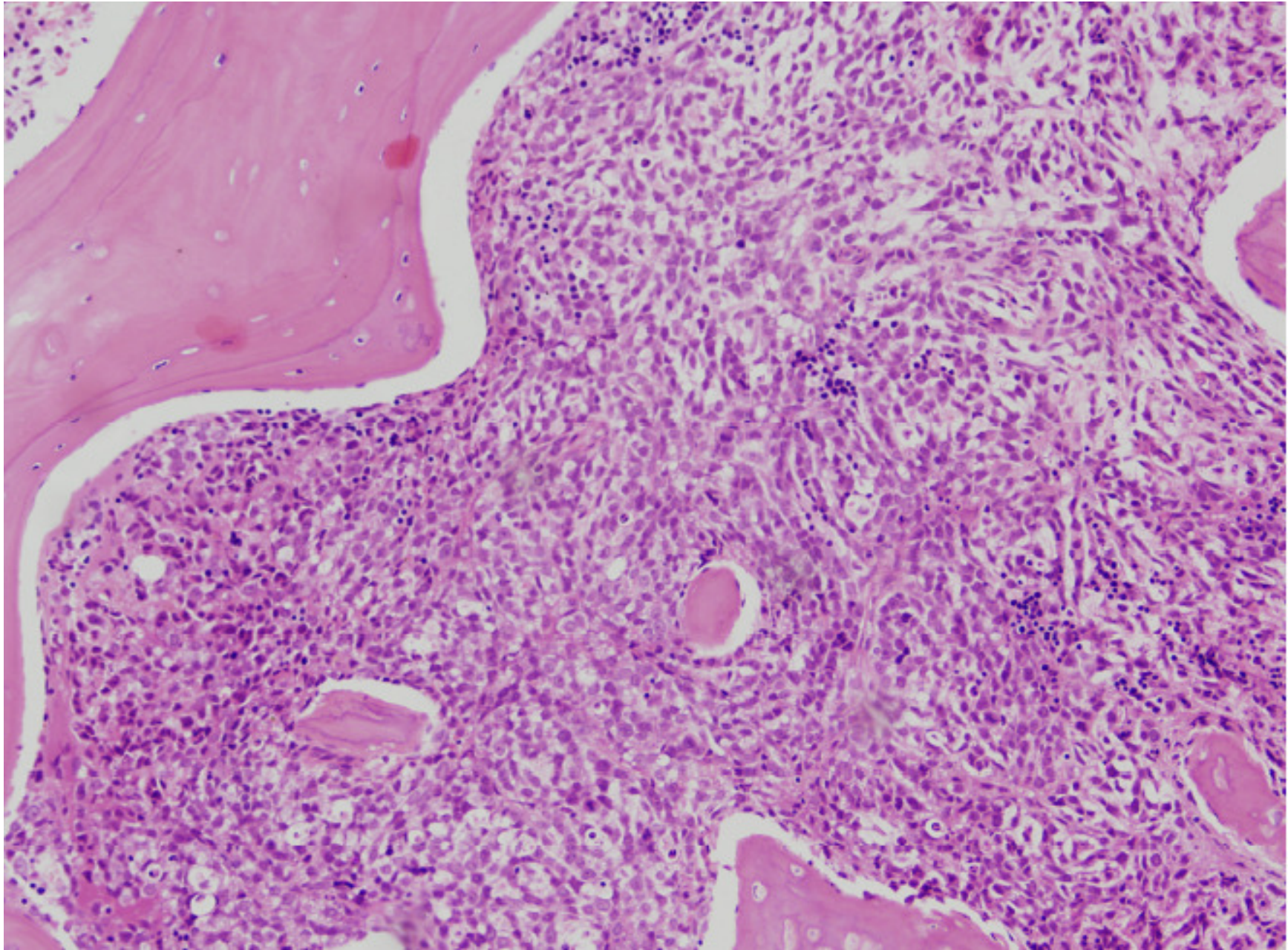
Bone Marrow aspirate Dual Esterase x400



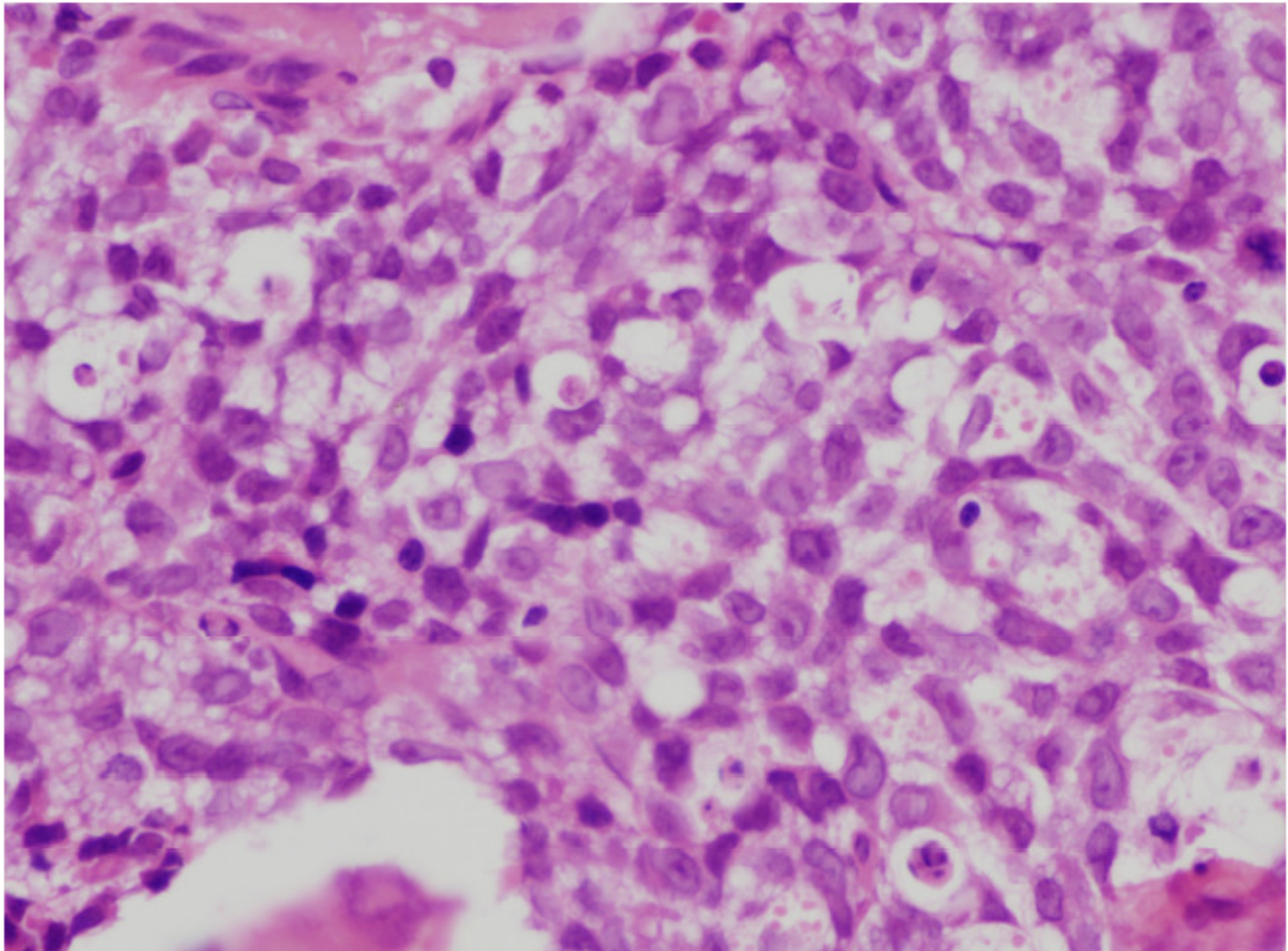
Bone Marrow aspirate Sudan
Black B x600



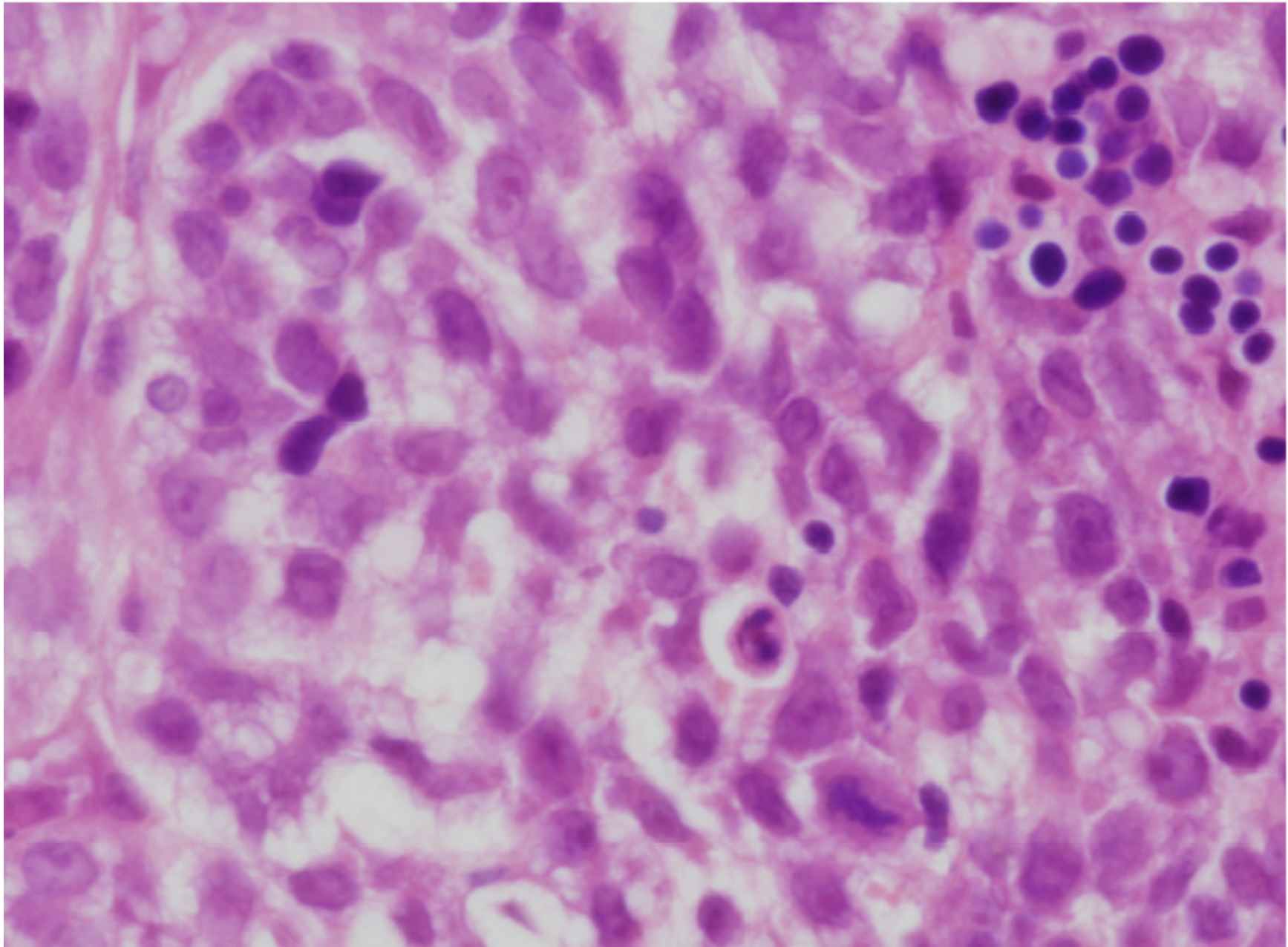
Bone Marrow trephine H&E x100



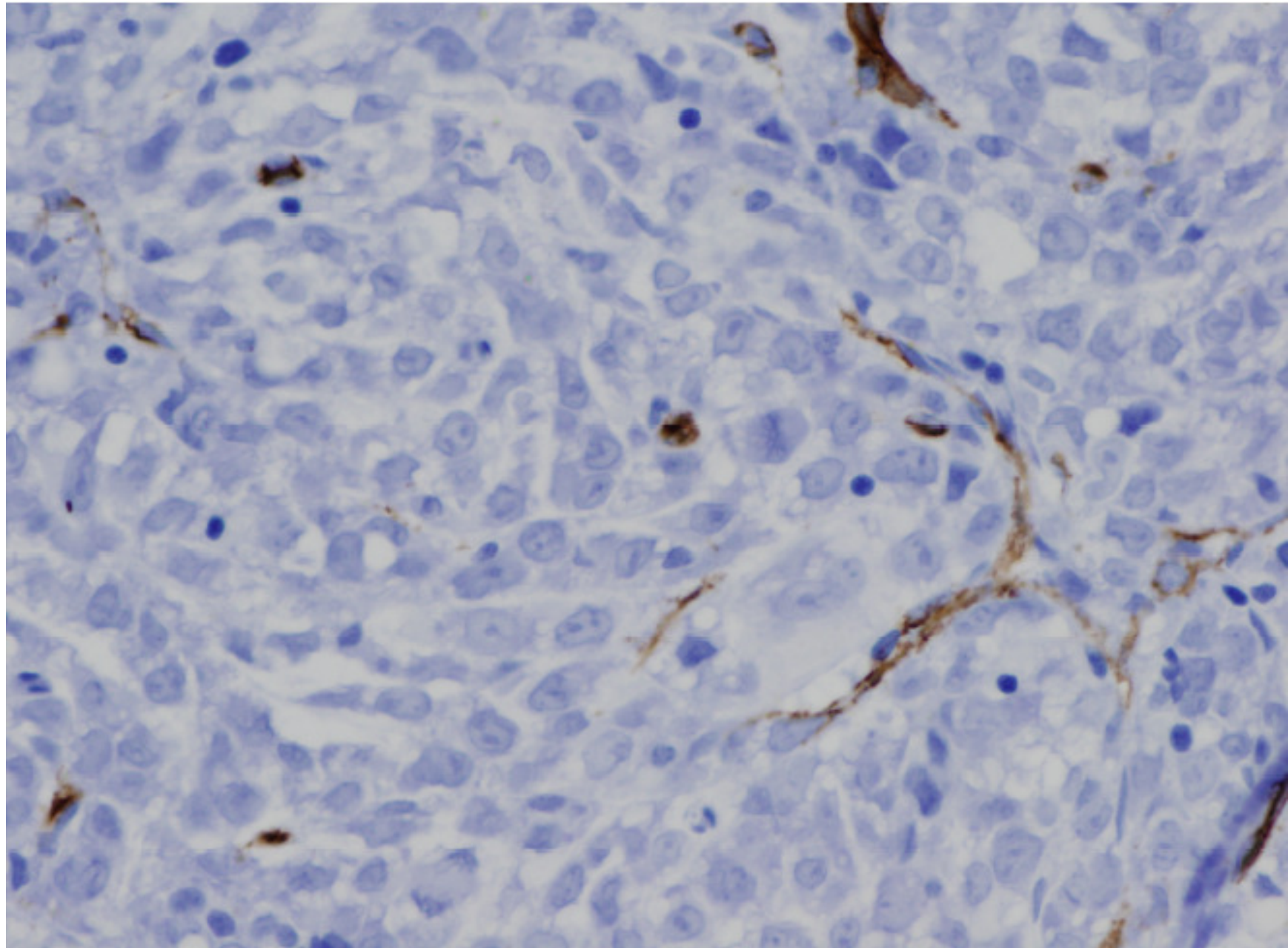
Bone Marrow trephine H&E x400



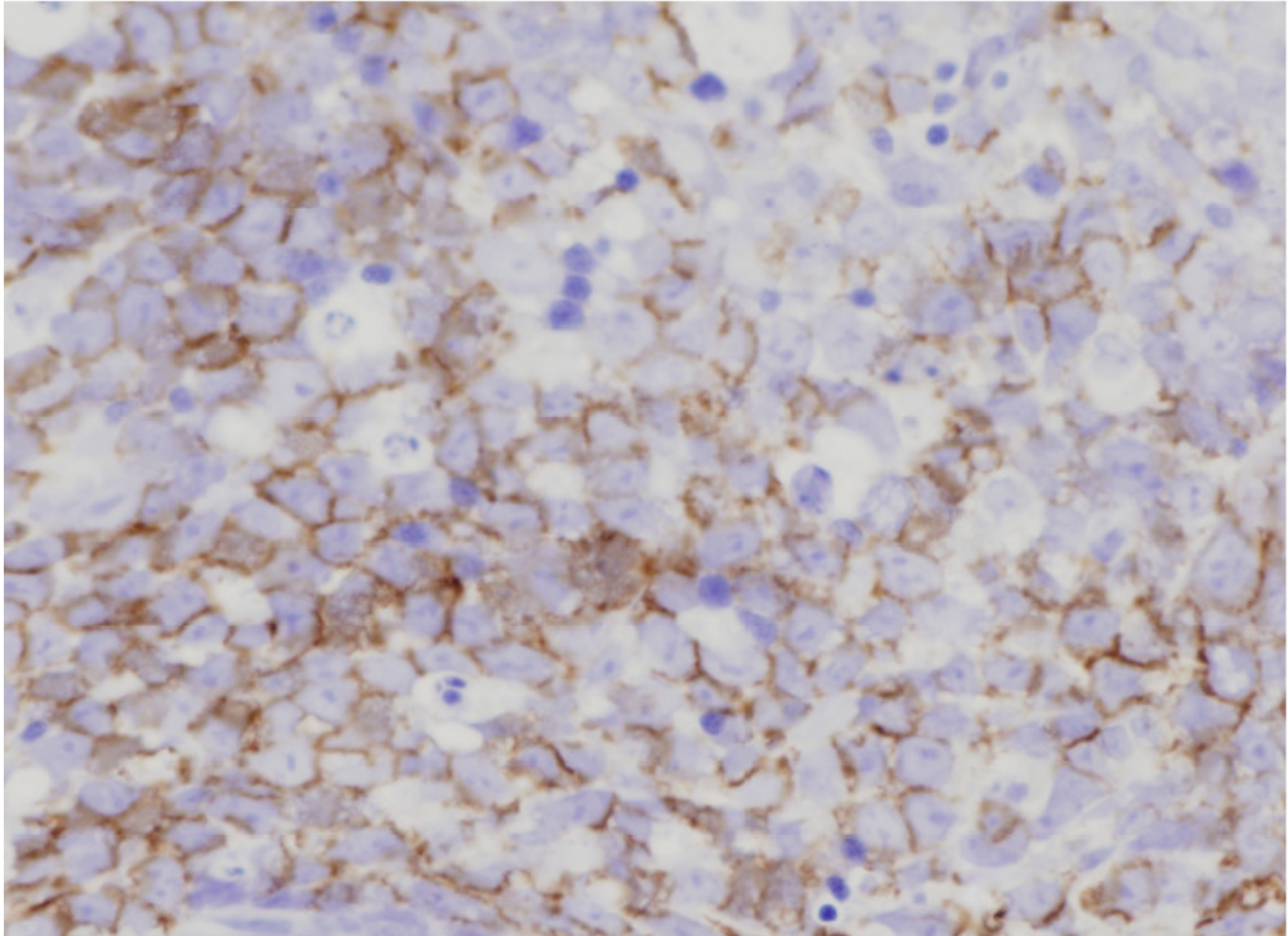
Bone Marrow trephine H&E x600



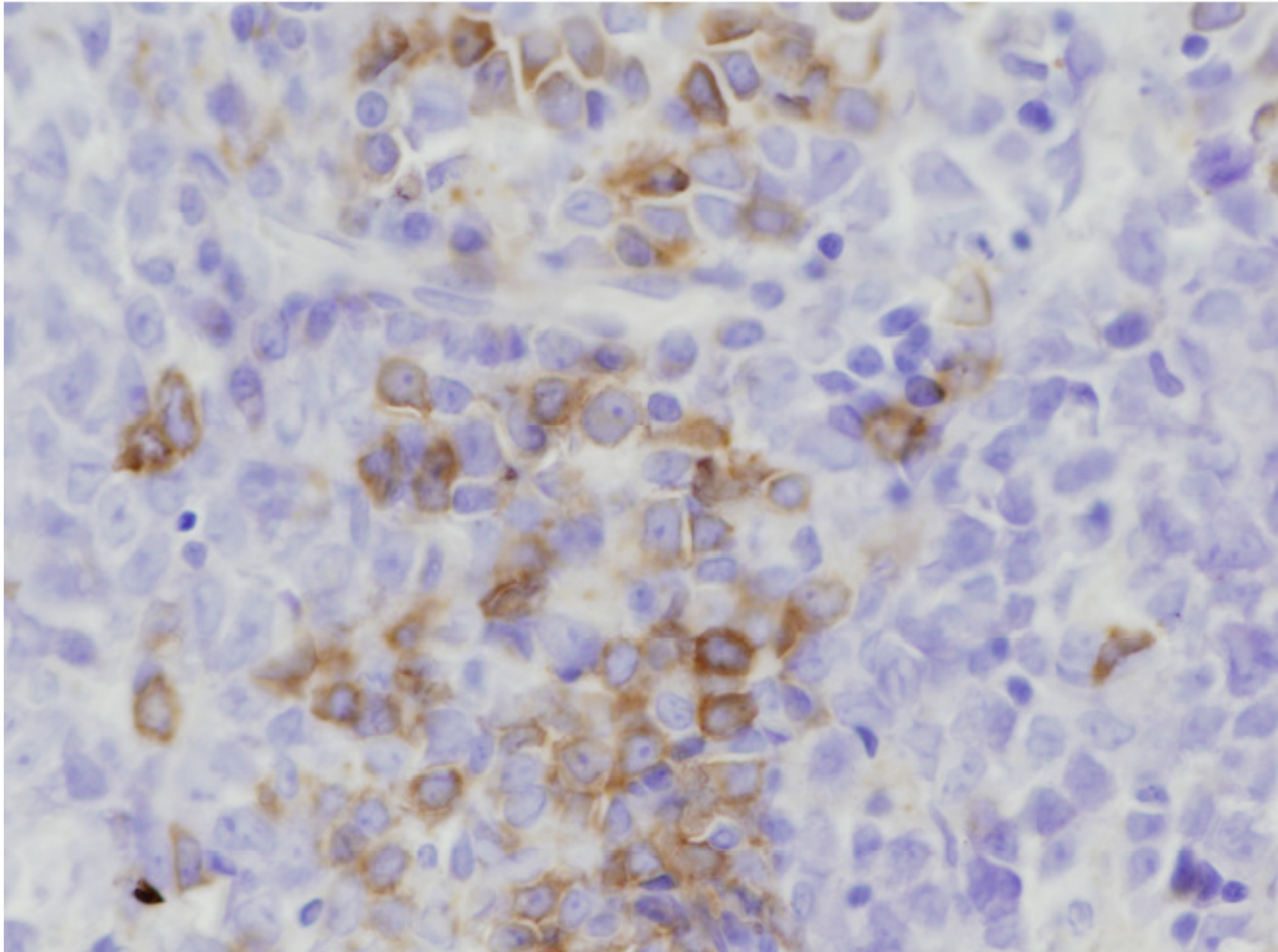
Bone Marrow trephine CD34 x400



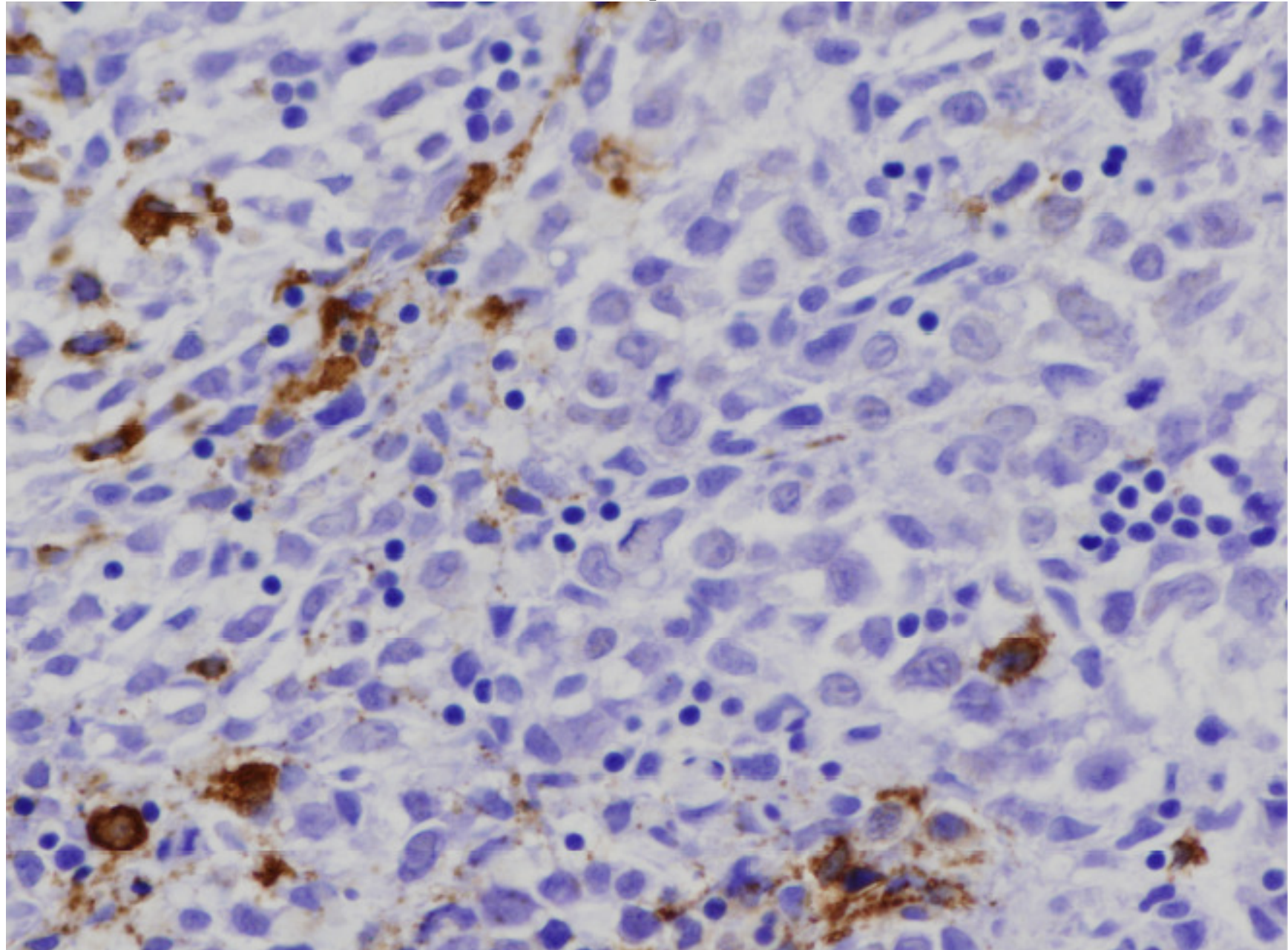
Bone Marrow trephine CD56 x400



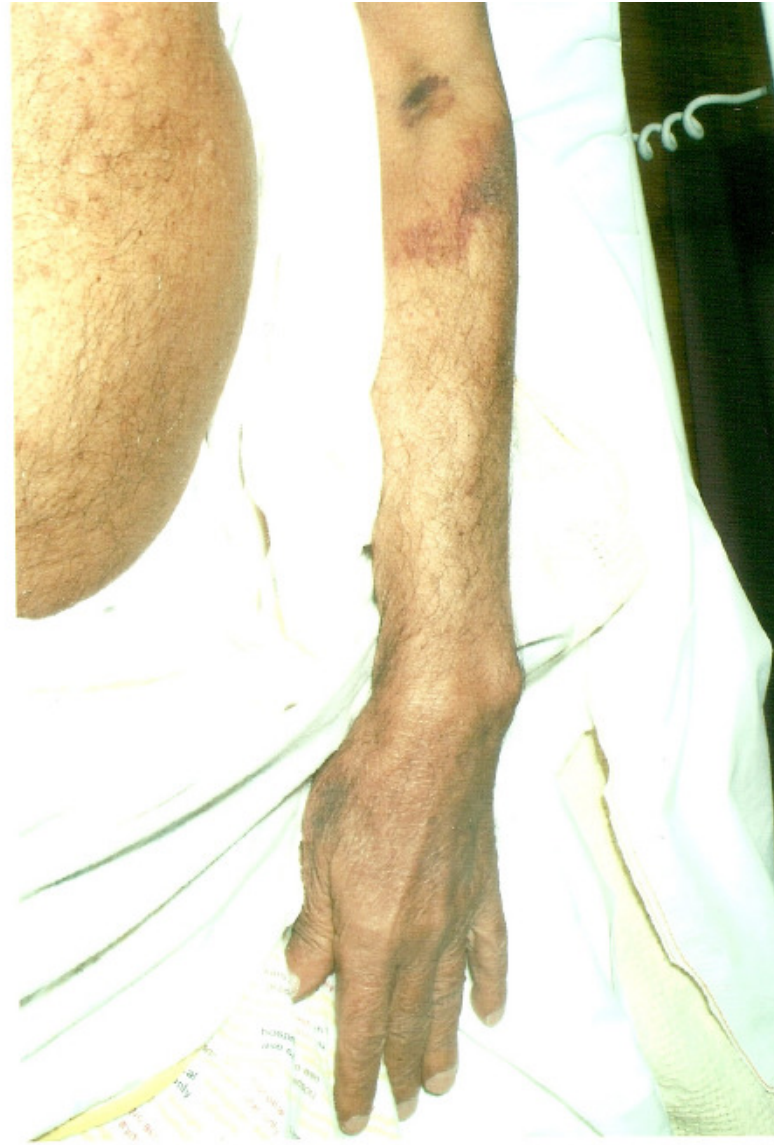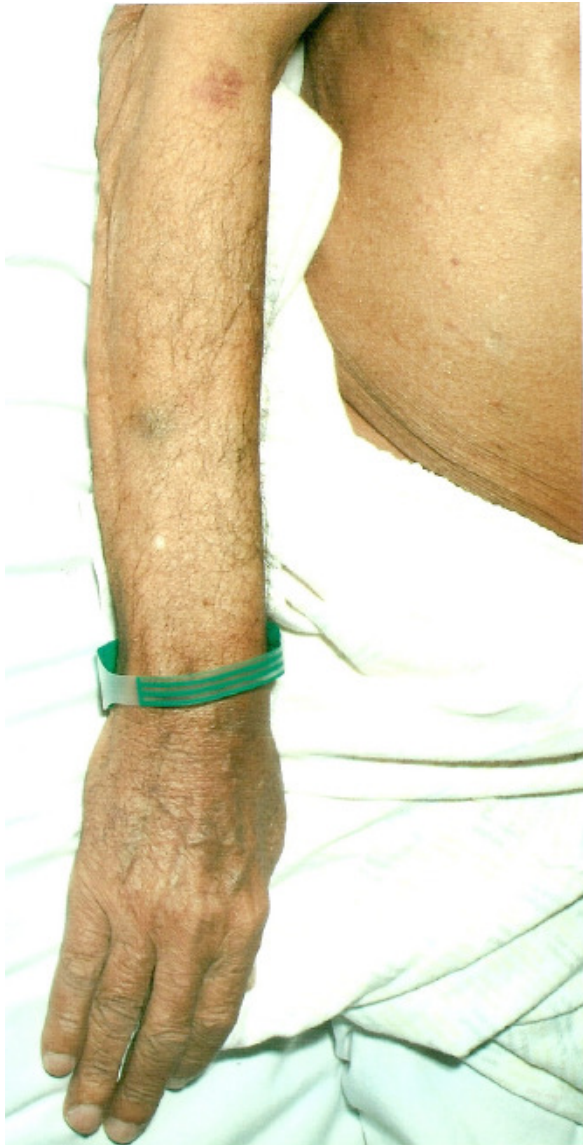Bone Marrow trephine CD117 x400



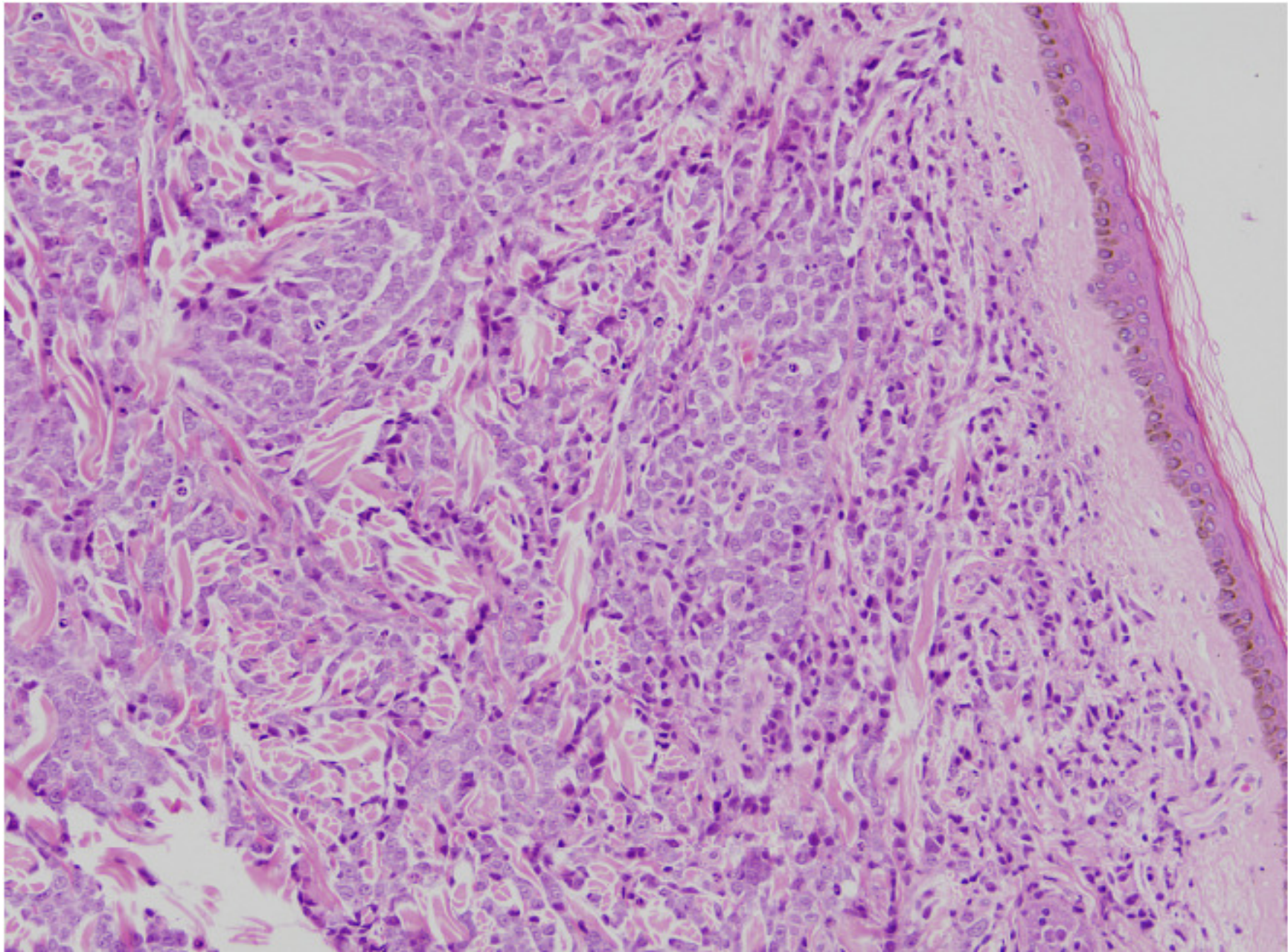
Bone Marrow trephine MPO x400



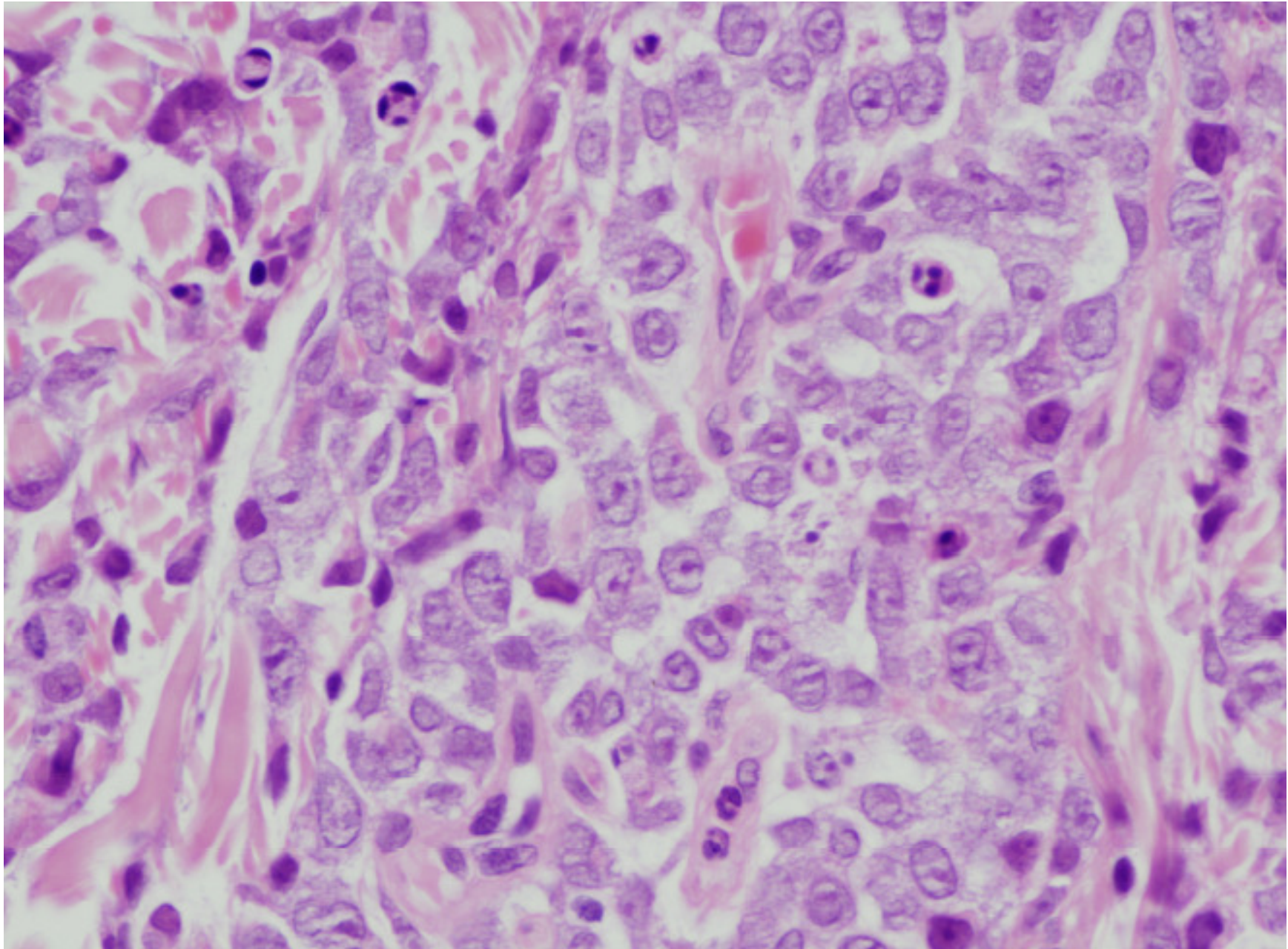
Clinical examination: Skin



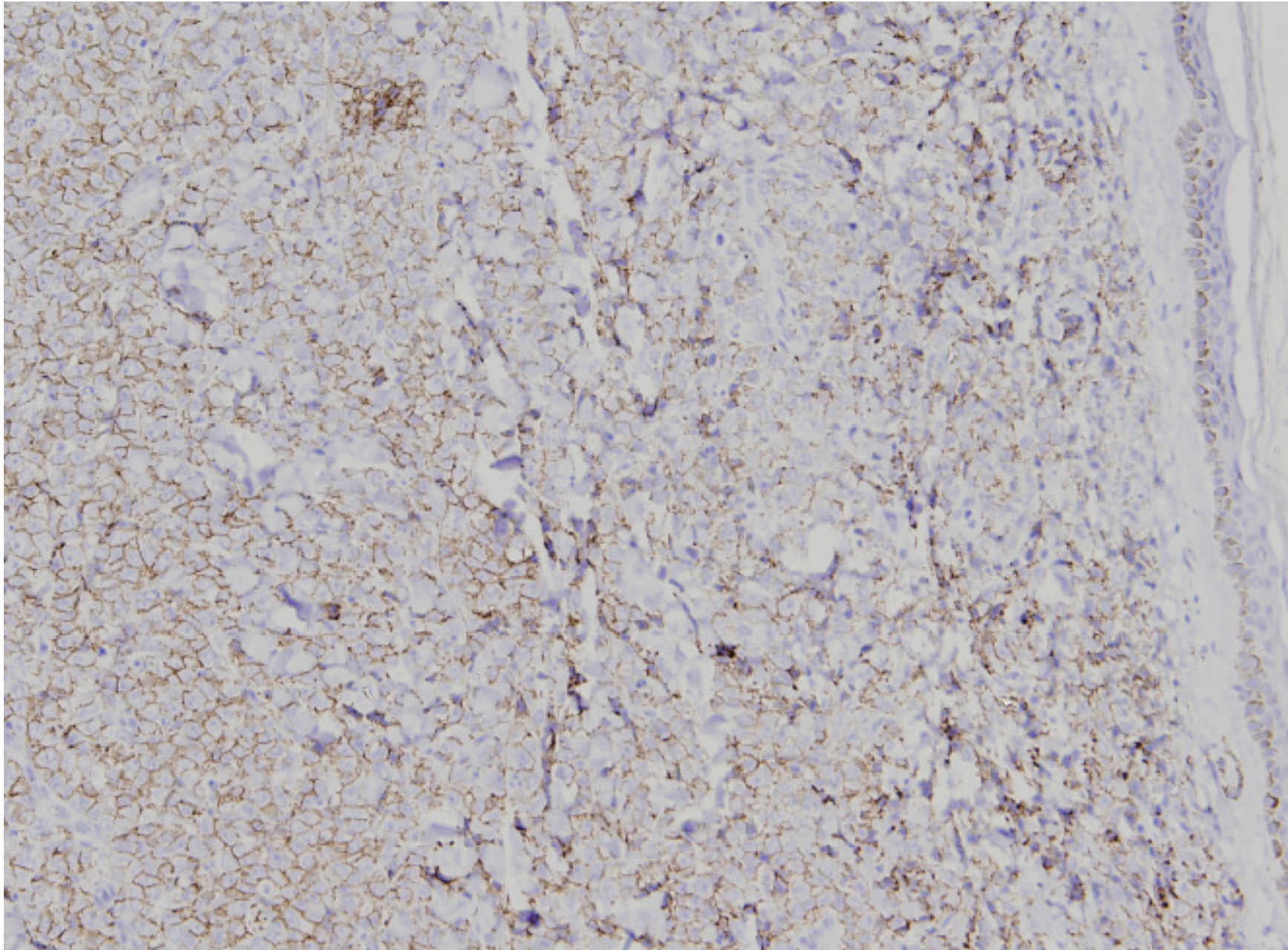
Skin biopsy H&E x100



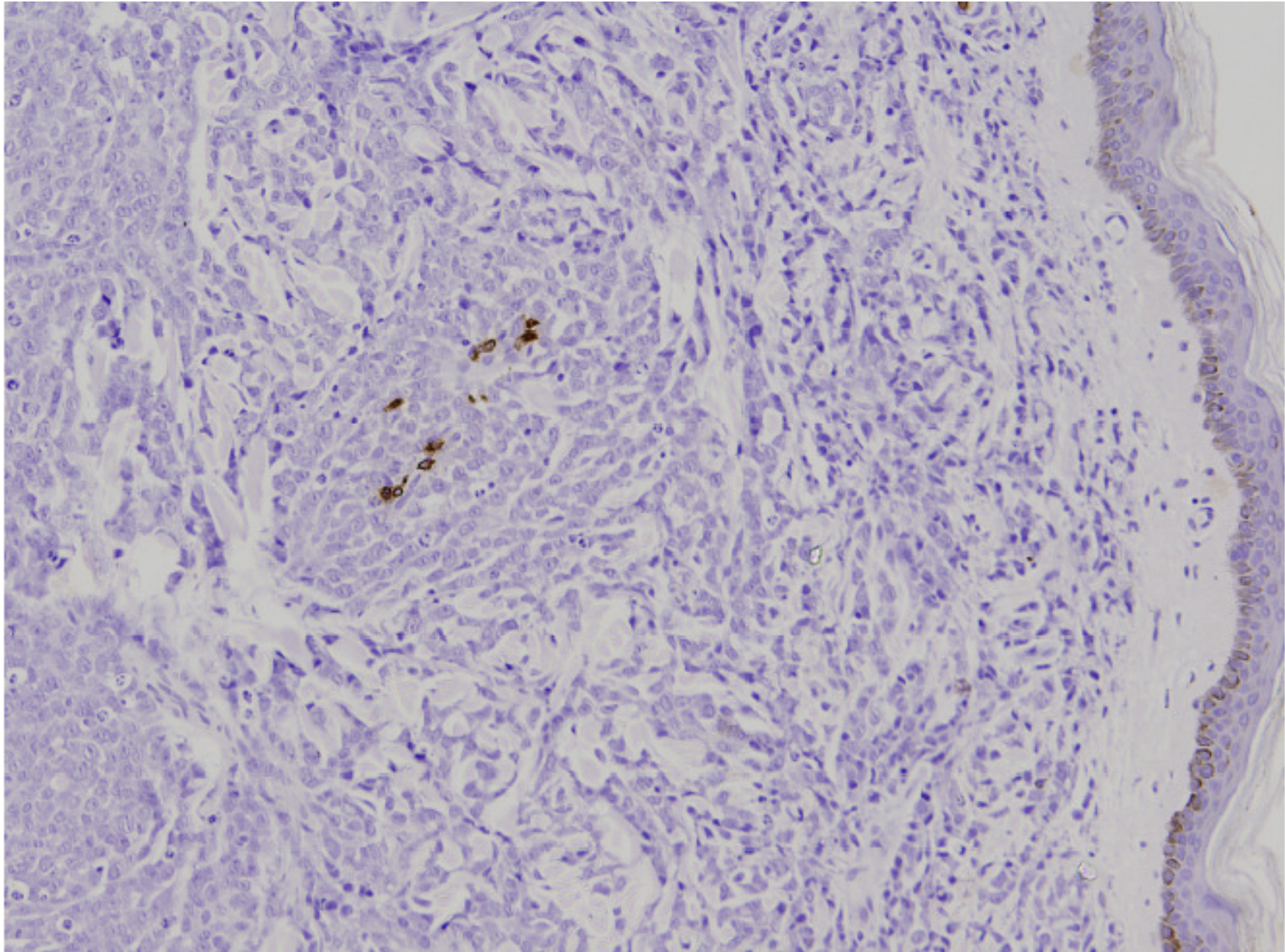
Skin biopsy H&E x400



Skin biopsy CD56 x400



Skin biopsy MPO x400



Conclusion

- Poorly differentiated acute myeloid leukaemia with monocytoid features:
 - CD34 negative
 - expresses CD15, CD56 and lysozyme
 - aberrant expression of CD14 and CD64
 - with skin and organ infiltration